



Heart-to-Heart:

CPT Coding for
Congenital Heart Cath

Disclaimer:

This presentation is intended for educational purposes only. It aims to provide accurate and reliable information on the subject matter. While every effort has been made to ensure the accuracy of the content, the final responsibility rests with the user. I do not hold the copyright for CPT codes or ICD-10-CM.

Amy Clay, CCS, CIRCC



- Almost 25 years coding experience working at hospitals across the US
- Interventional Radiology for NewYork Presbyterian
- Education Officer
- AmyClay@CodingConduit.com

CIRCC Certification

- Submit 20 core and 16 specialty CEUs every 2 years:
 - zHealth: \$35 per CEU (\$31 with membership)
 - Free CEUs: www.zhealthpublishing.com/seminars-and-webinars/webinars
 - medicalassetmanagement.com: \$30 per CEU (2023)
 - E-mail Orientia.Speakman@medicalassetmanagement.com
 - medlearn.com: \$153.50 per CEU
 - www.medlearn.com/product-category/webcasts/
- AAPC membership: \$222 per year

CIRCC Certification

- Other CEU opportunities:
 - RadRX with Stacie Buck:
 - <https://radrx.com/education/webinars/>
- AAPC website:
 - Look under Training and Events, then filter by certification
 - <https://www.aapc.com/medical-coding-education/ceusearch/ceusearch.aspx>

01

Heart Anatomy

02

Cardiac Catheterization


03

Heart Anomalies

04

Examples

Why Cover Congenital Caths?



1% of babies are born with a ***congenital*** heart defect

1 in 4 have a ***critical*** heart defect

85% will ***survive*** to adulthood

Today, adults ***outnumber*** children living with CHD

Things to Remember



- 1) Is this a normal or abnormal connection?
- 2) Was the catheter placed in the right, left or both sides of heart?
- 3) What is the location of the angiograms?

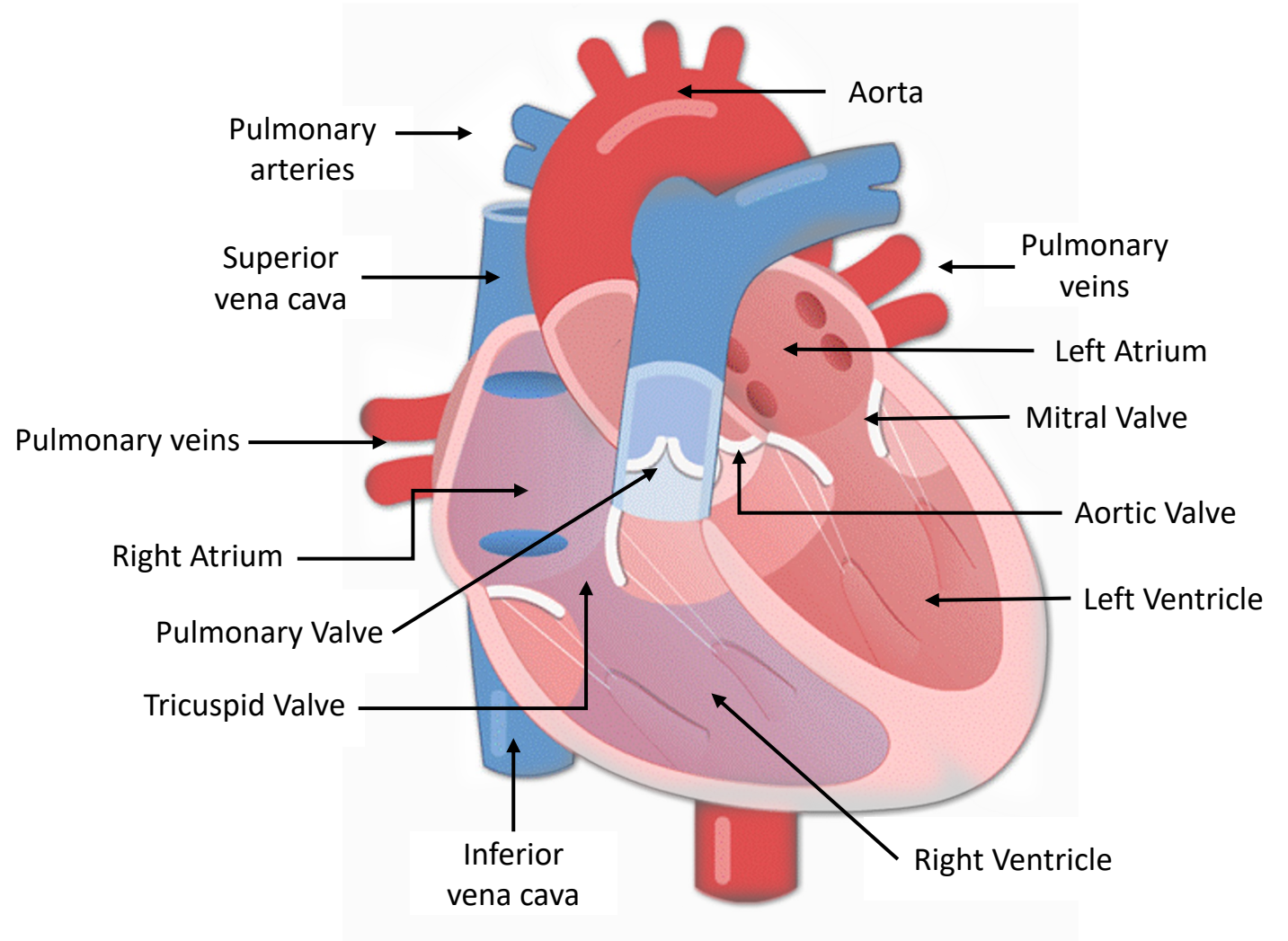
Heart Anatomy

4 Chambers

- Right Atrium
- Right Ventricle
- Left Atrium
- Left Ventricle

4 Valves

- Tricuspid Valve
- Pulmonary Valve
- Mitral Valve
- Aortic Valve



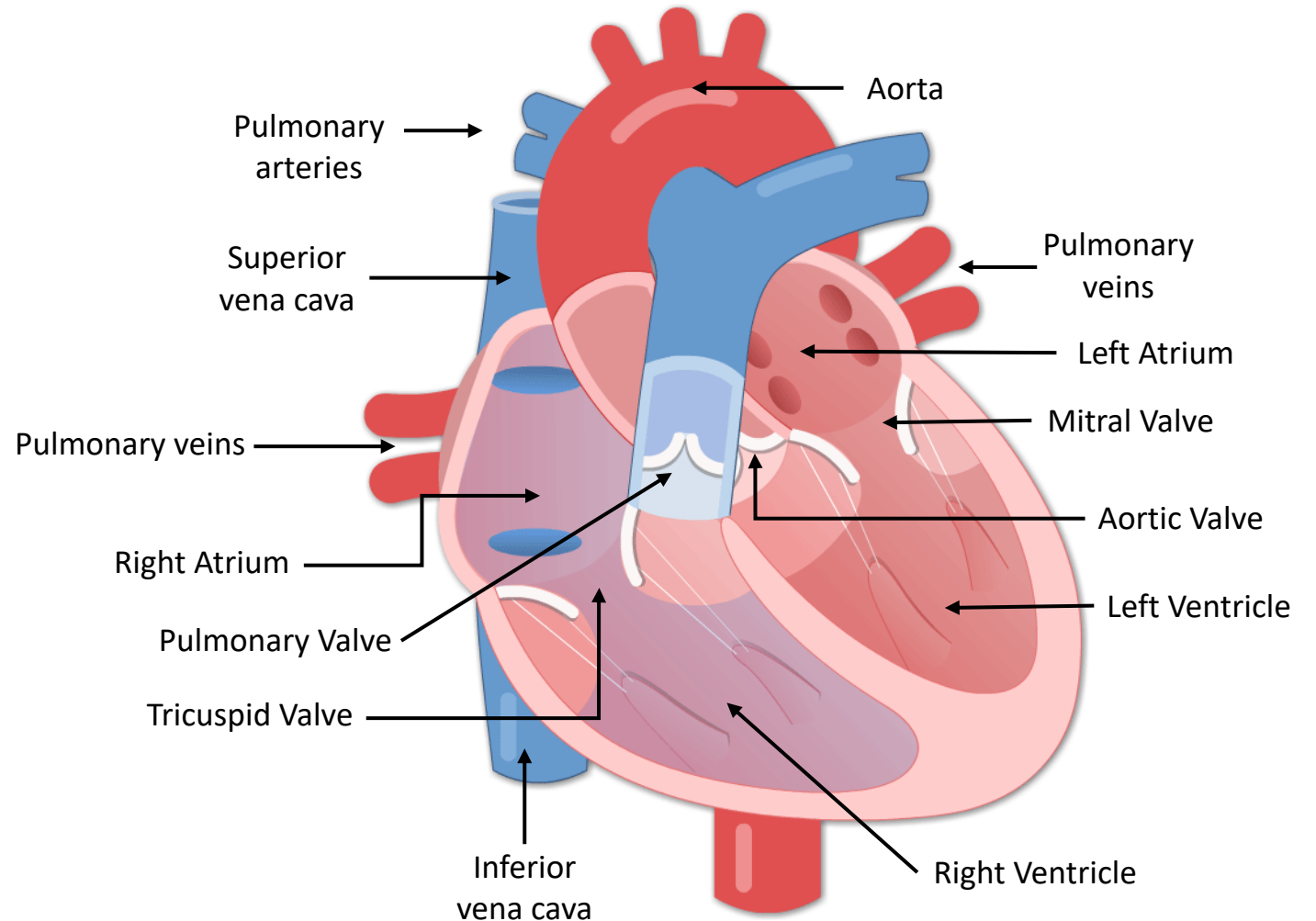
Heart Anatomy

4 Chambers


- Right Atrium
- Right Ventricle
- Left Atrium
- Left Ventricle

4 Valves

- Tricuspid Valve
- Pulmonary Valve
- Mitral Valve
- Aortic Valve




Congenital Heart Caths: 2 Categories

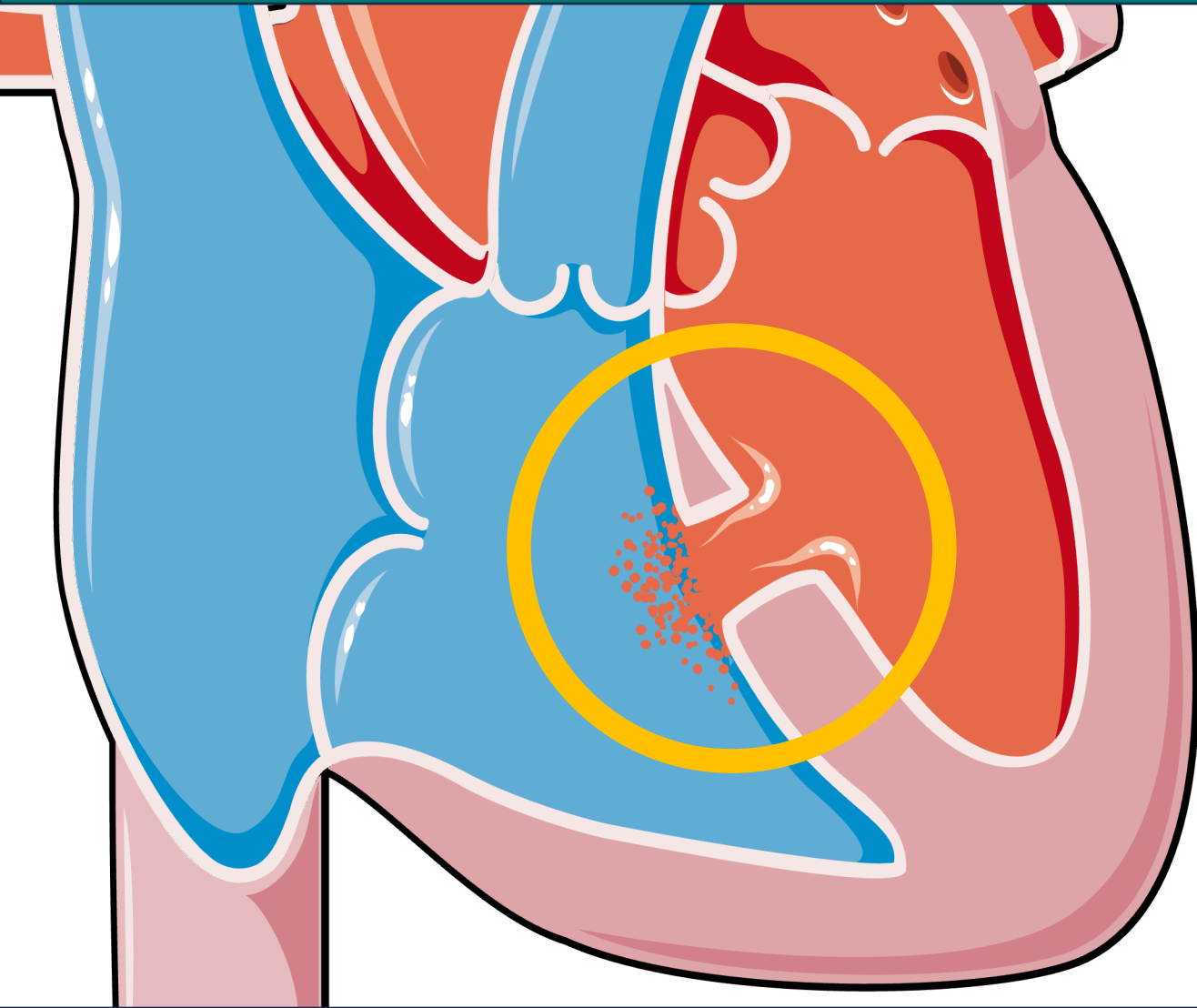


Abnormal Connections
= Cyanosis

Normal Connections
= Acyanosis



Normal Connection: Ventricular Septal Defect



An opening or defect in the septum separating the two ventricles of the heart

Causes higher pressure in the heart or reduced oxygen to the body

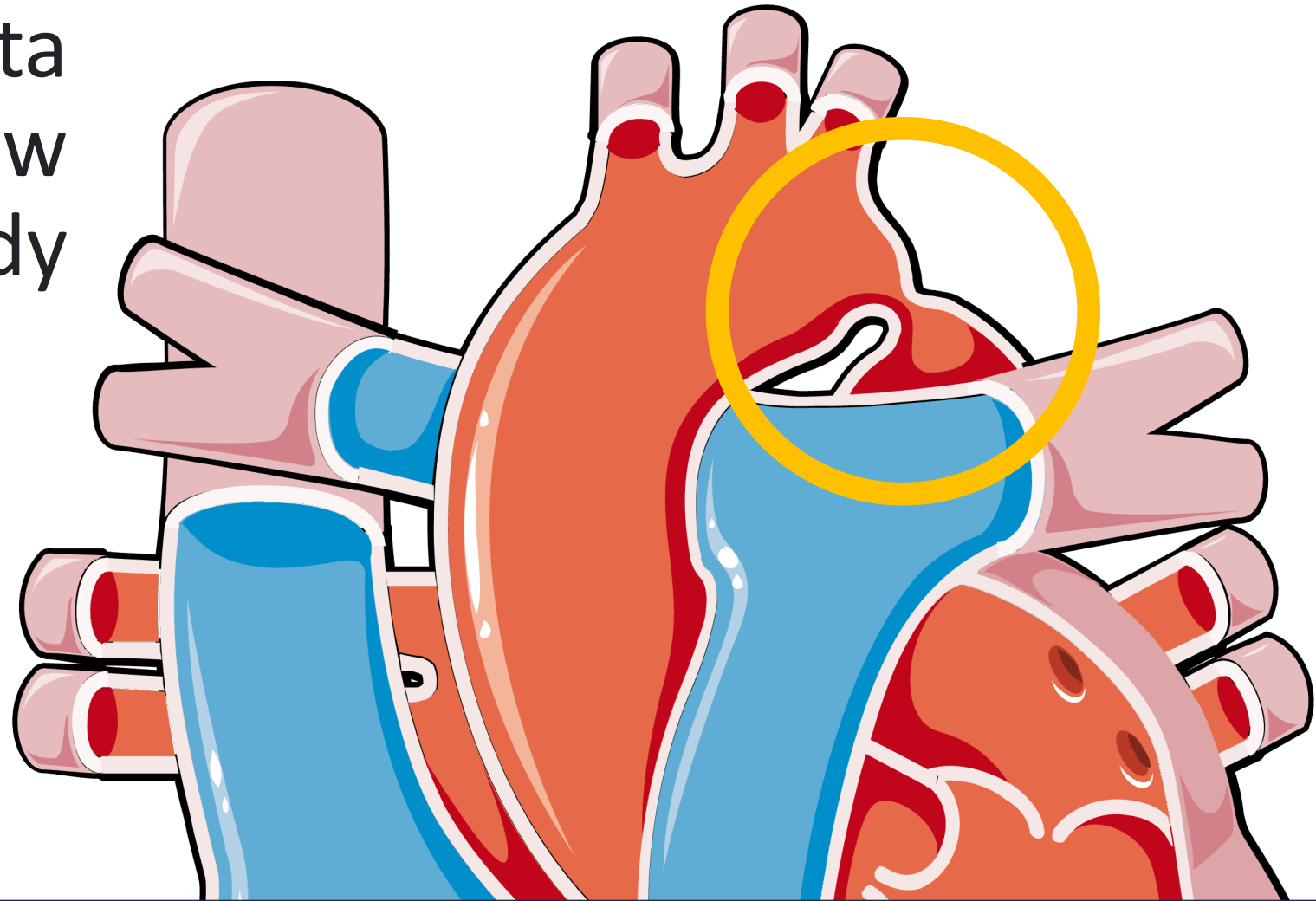
VSD - Q21.0

Normal Connection: Coarctation of the Aorta

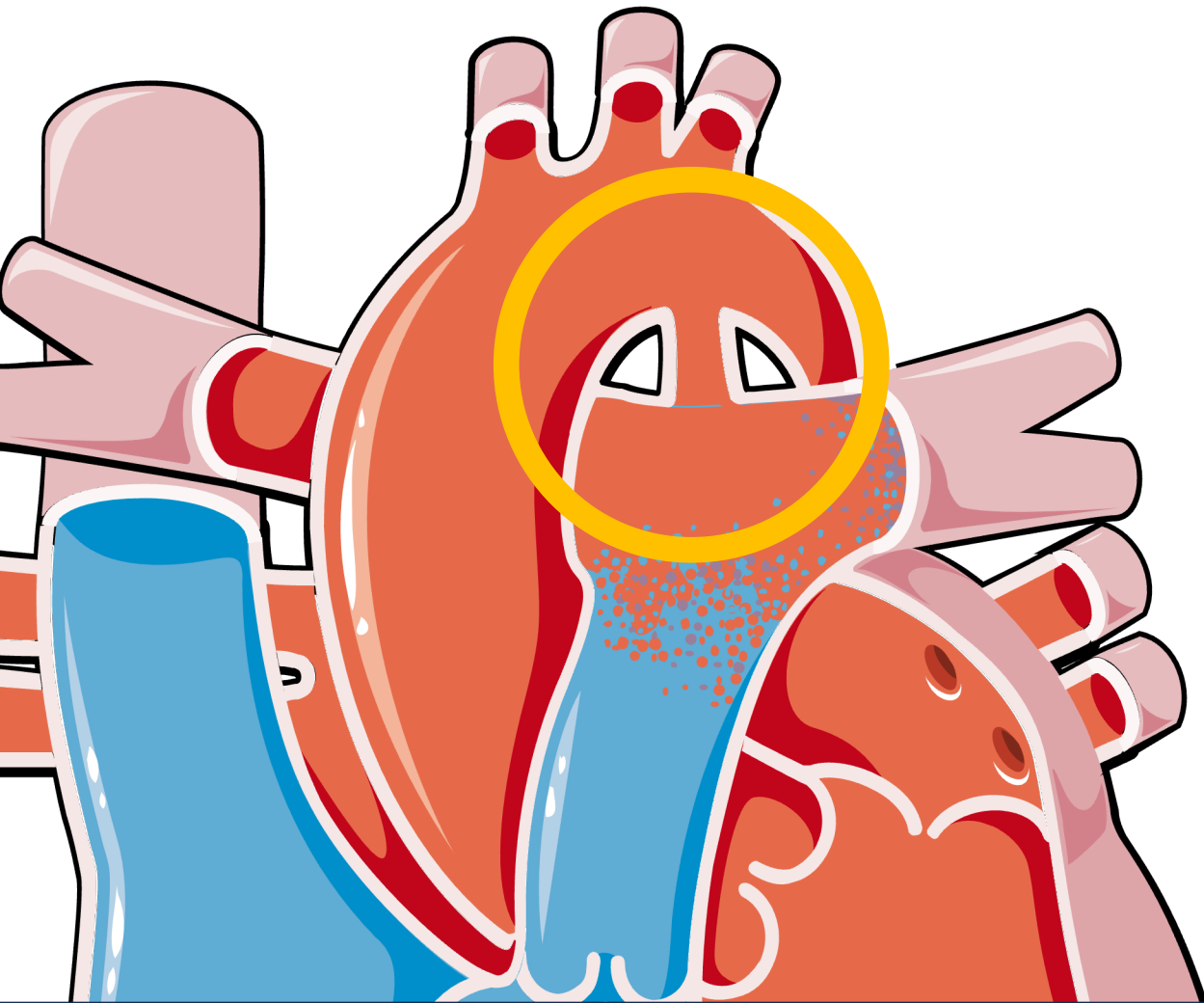
Narrowing of the aorta which affects blood flow to the rest of the body

CoA can cause high blood pressure or heart damage

CoA – Q25.1



Normal Connection: Patent Ductus Arteriosus



Artery connecting the aorta and the pulmonary artery

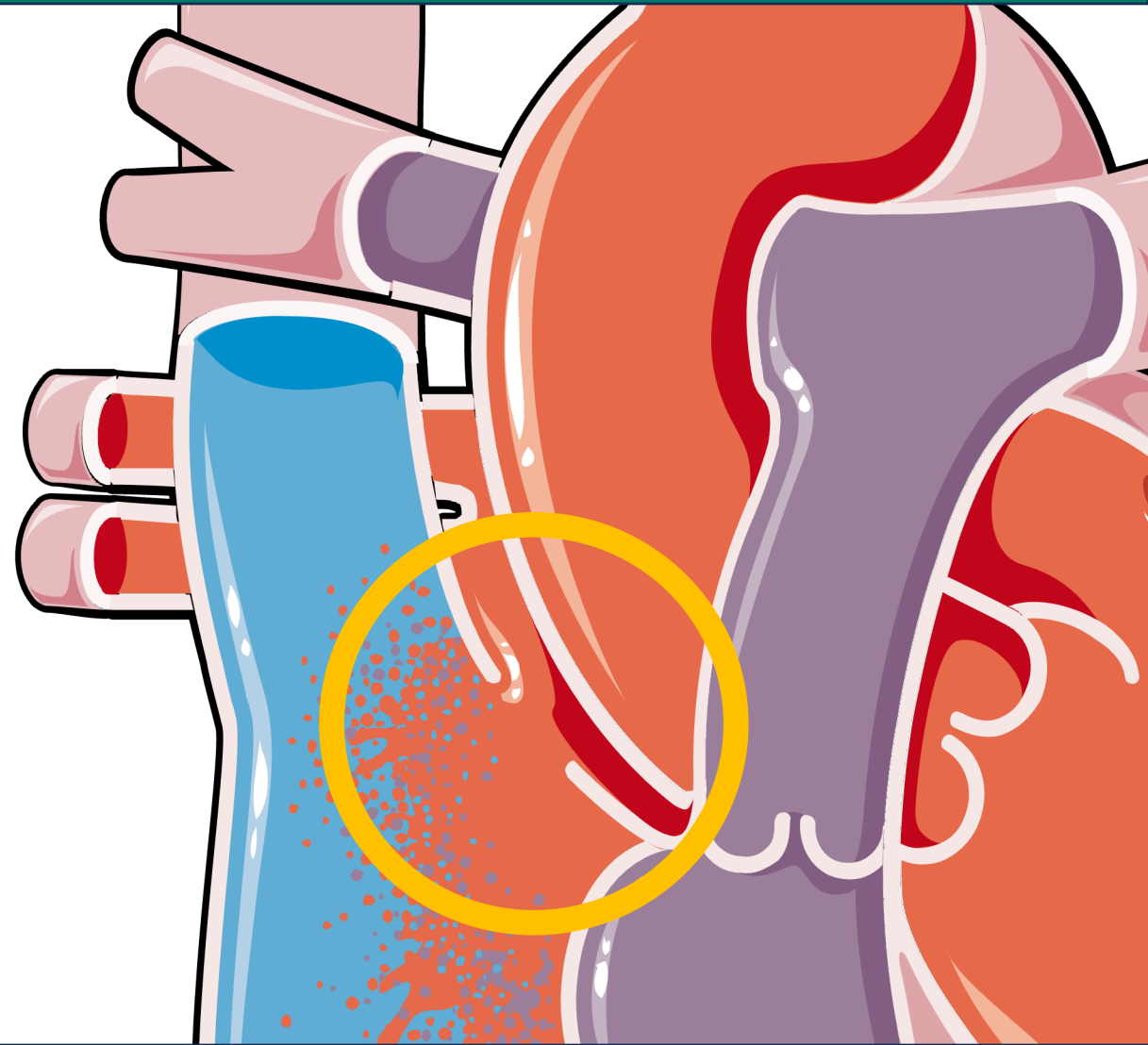
Pressure will increase in the pulmonary arteries, resulting in pulmonary hypertension

PDA – Q25.0

Normal Connection: Atrial Septal Defect

An opening or defect in the septum separating the two atria of the heart

ASD can lead to stroke, arrhythmia and pulmonary hypertension.



Normal Connection: Atrial Septal Defect

Q21.10 Atrial septal defect, unsp

 Q21.11 Secundum ASD

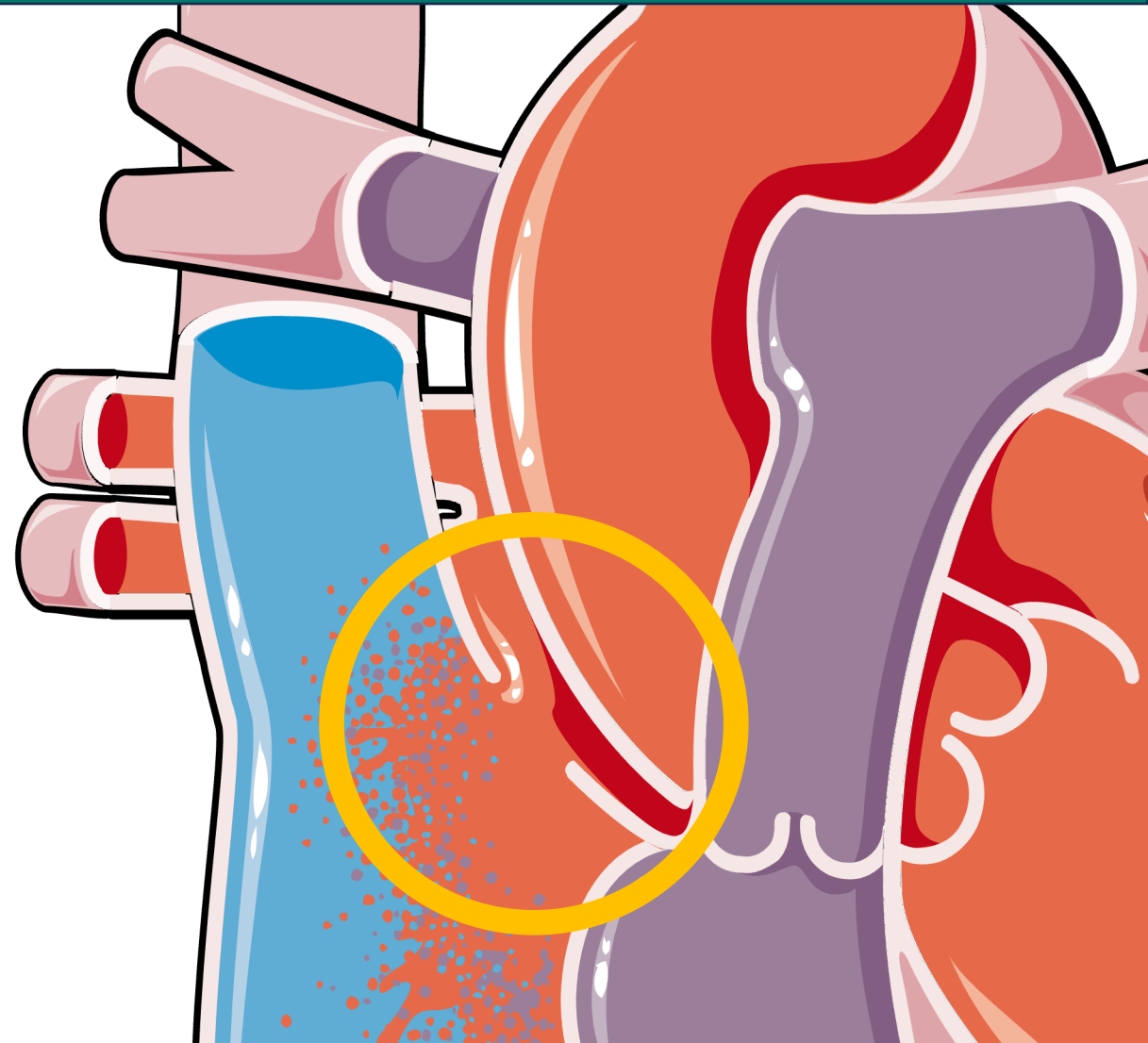
 Q21.13 Coronary sinus ASD

Q21.14 Superior sinus venosus ASD

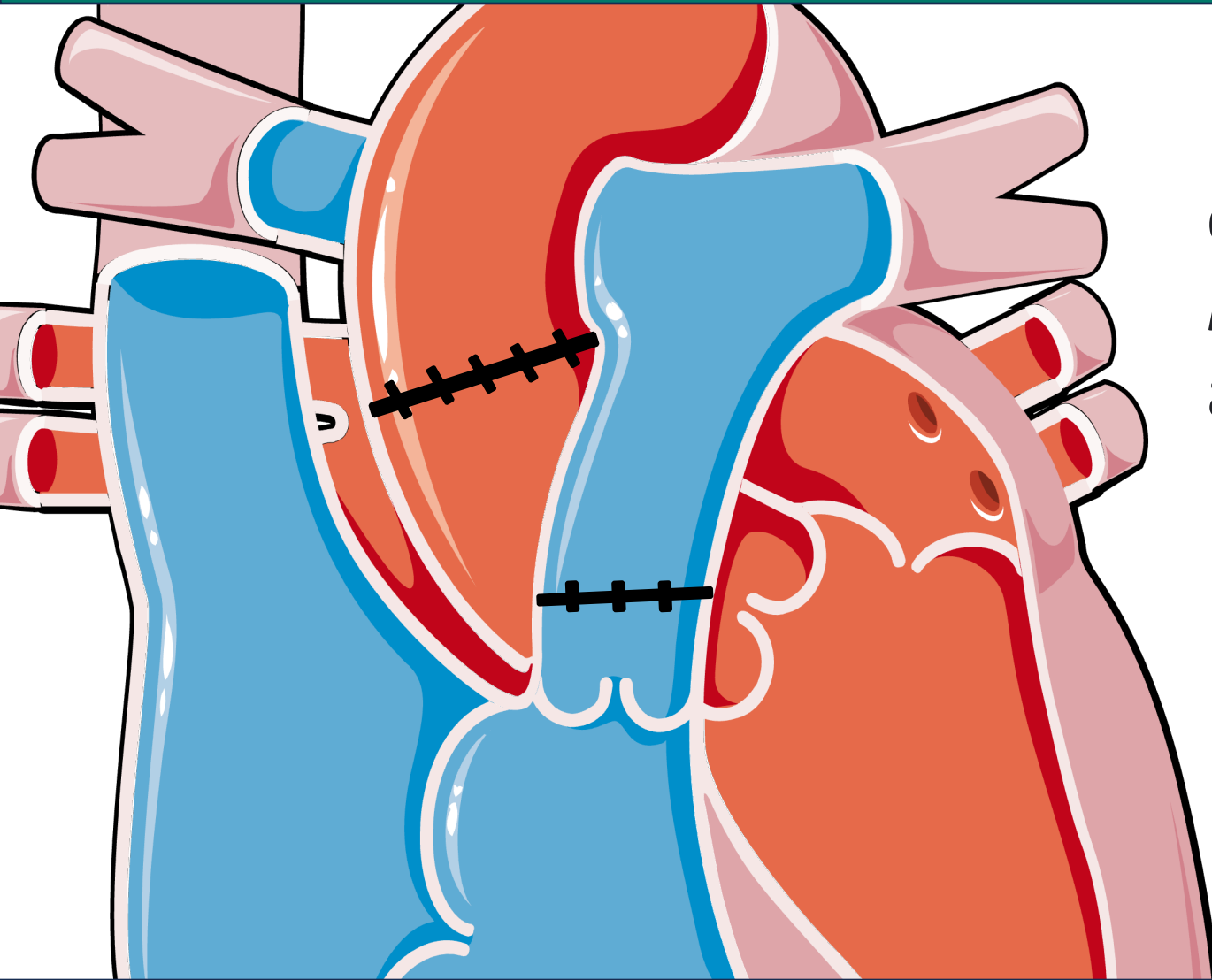
Q21.15 Inferior sinus venosus ASD

 Q21.16 Sinus venosus ASD, unsp

 Q21.19 Other specified ASD



Normal Connection: Repaired



If the abnormal connection can be repaired to restore *normal blood flow*, report it as a normal connection.

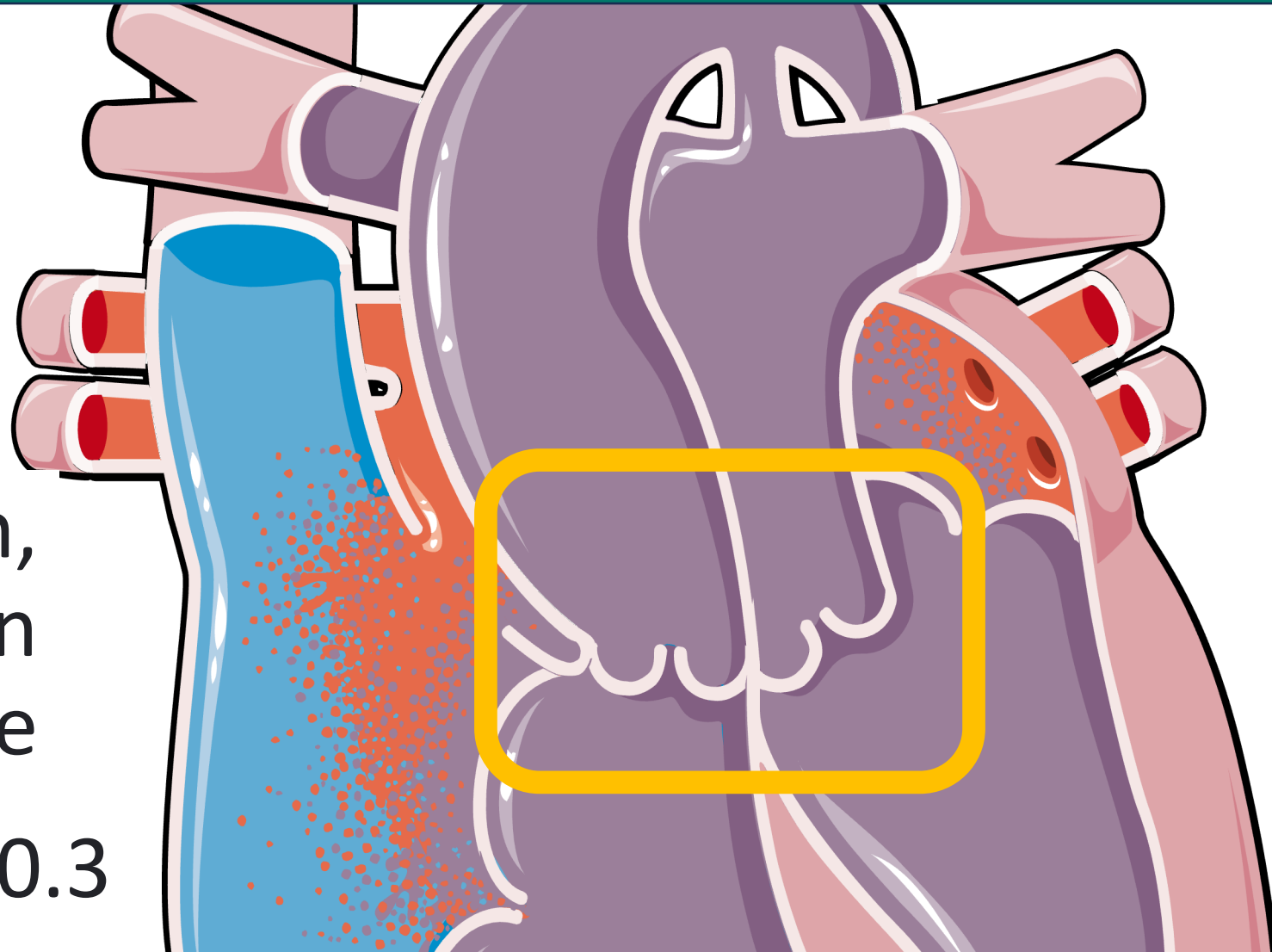
History of (corrected) congenital malformation of the heart and circulatory system - Z8774

Abnormal Conn: Transposition of Great Arteries

Aorta arises from the *right ventricle* and the pulmonary trunk arises from the *left ventricle*

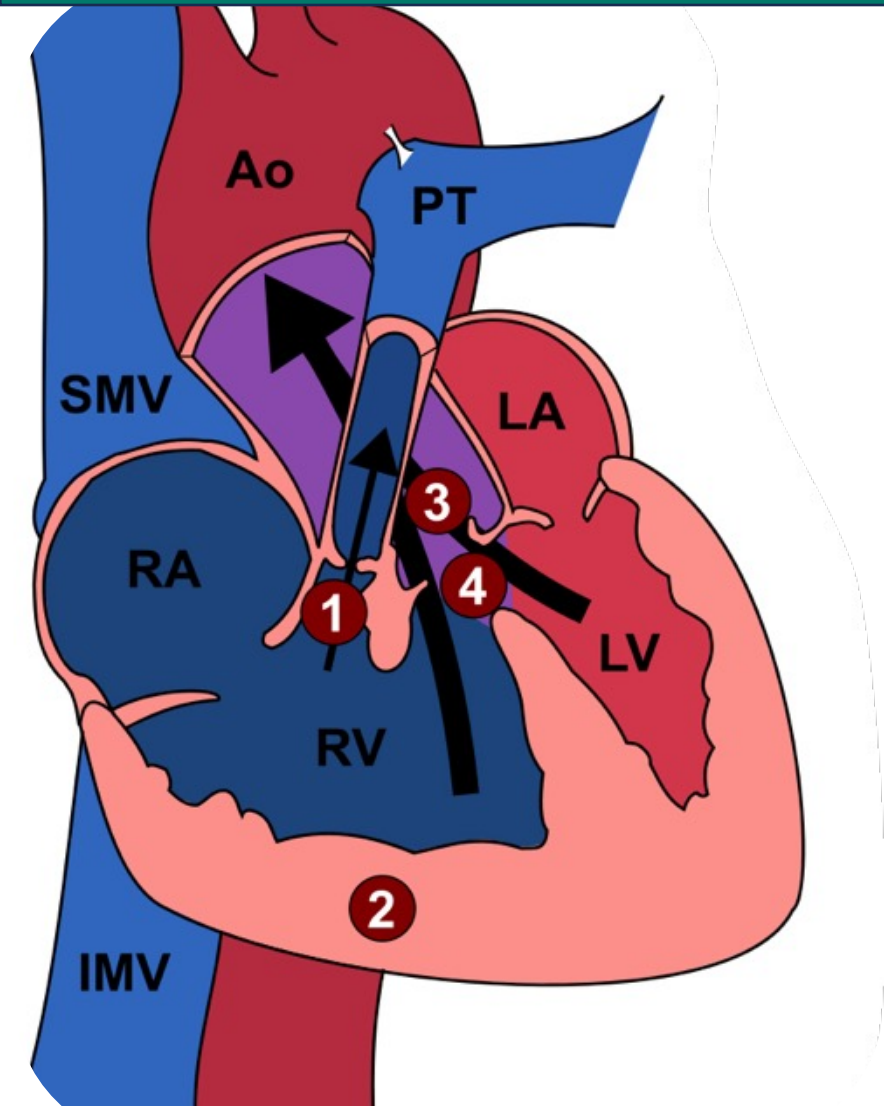
Cyanotic condition,
surgery performed in
the first week of life

TGA - Q20.3



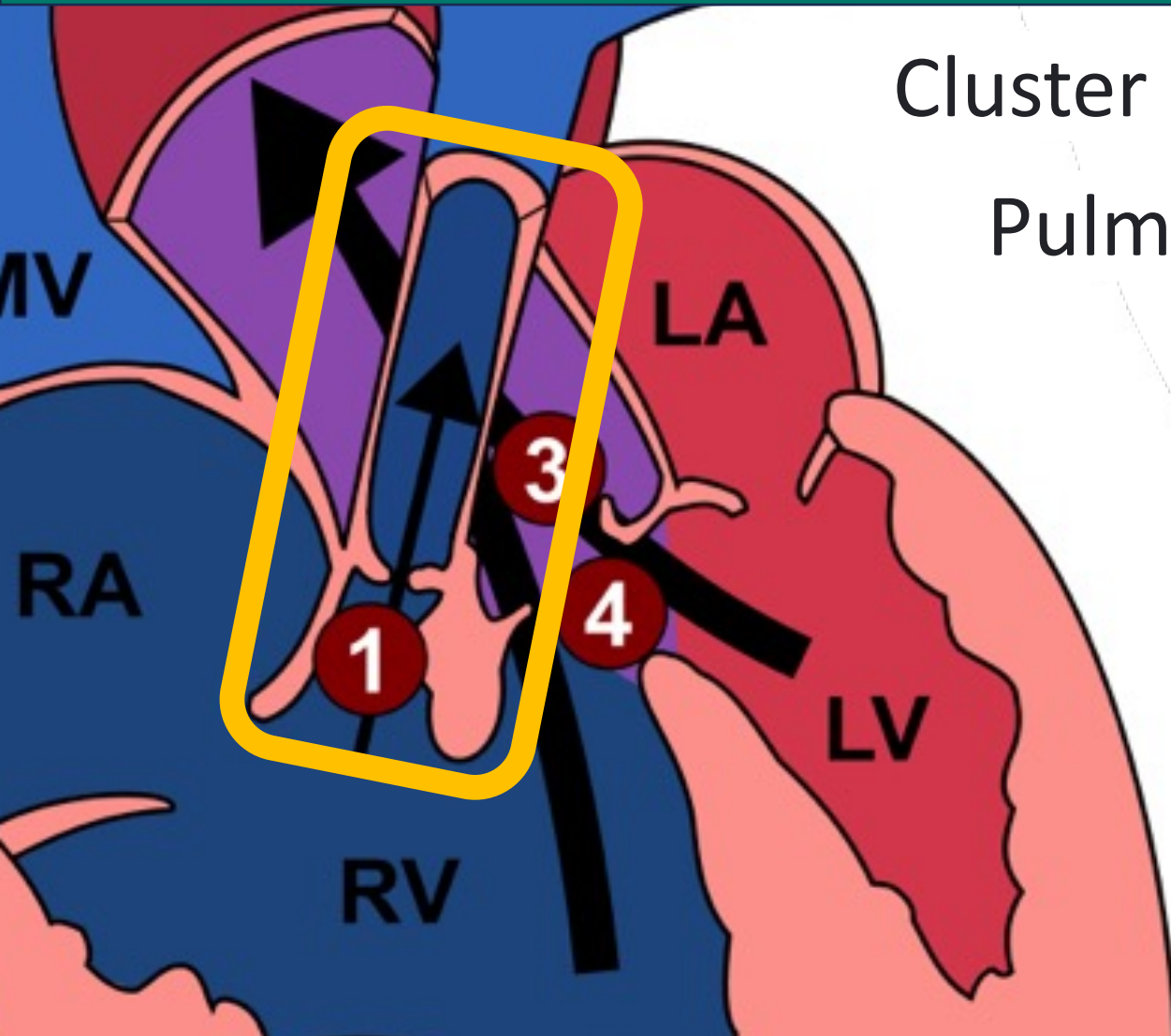
Abnormal Connection: Tetralogy of Fallot

Cluster of 4 anomalies:

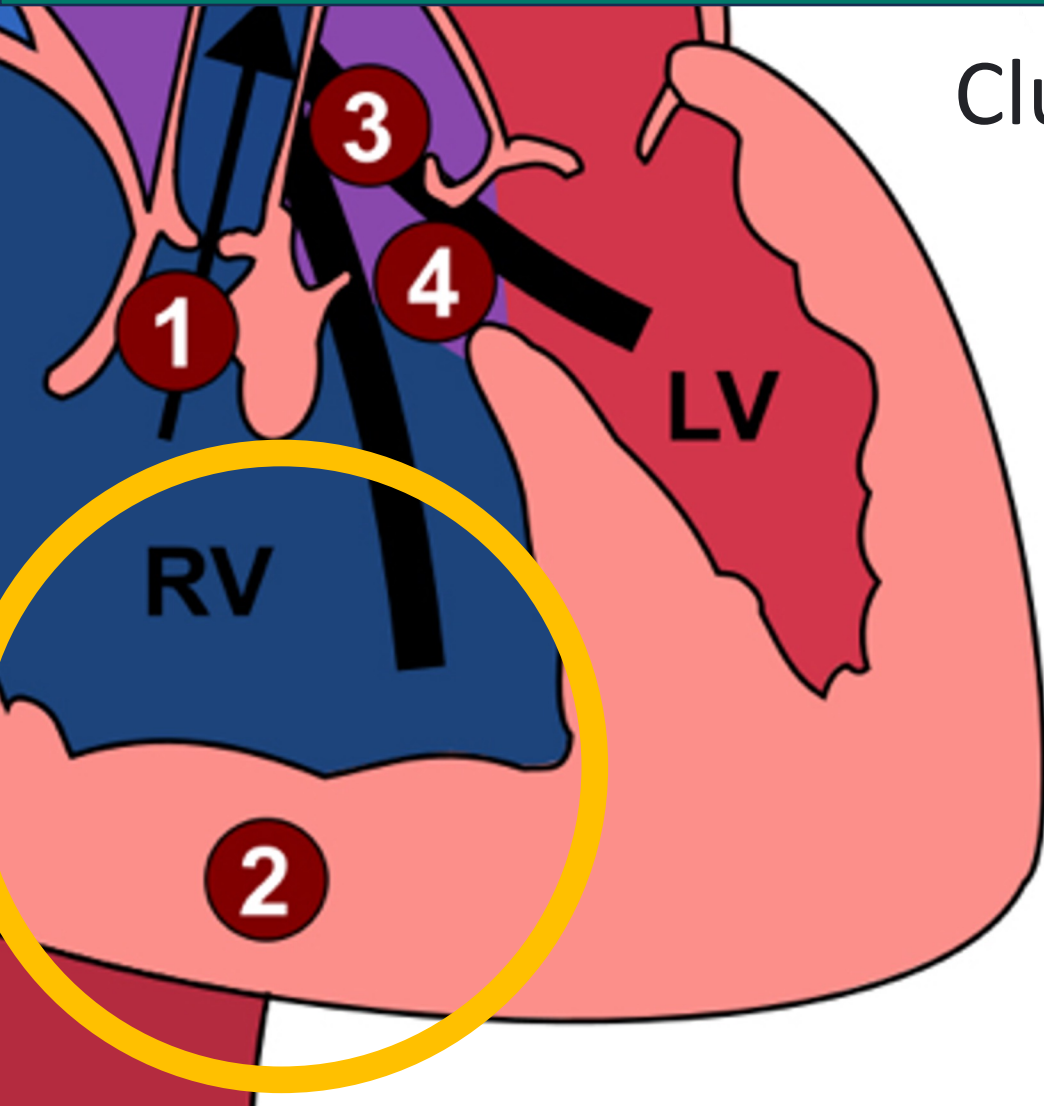


Abnormal Connection: Tetralogy of Fallot

Cluster of 4 anomalies:
Pulmonary Stenosis



Abnormal Connection: Tetralogy of Fallot

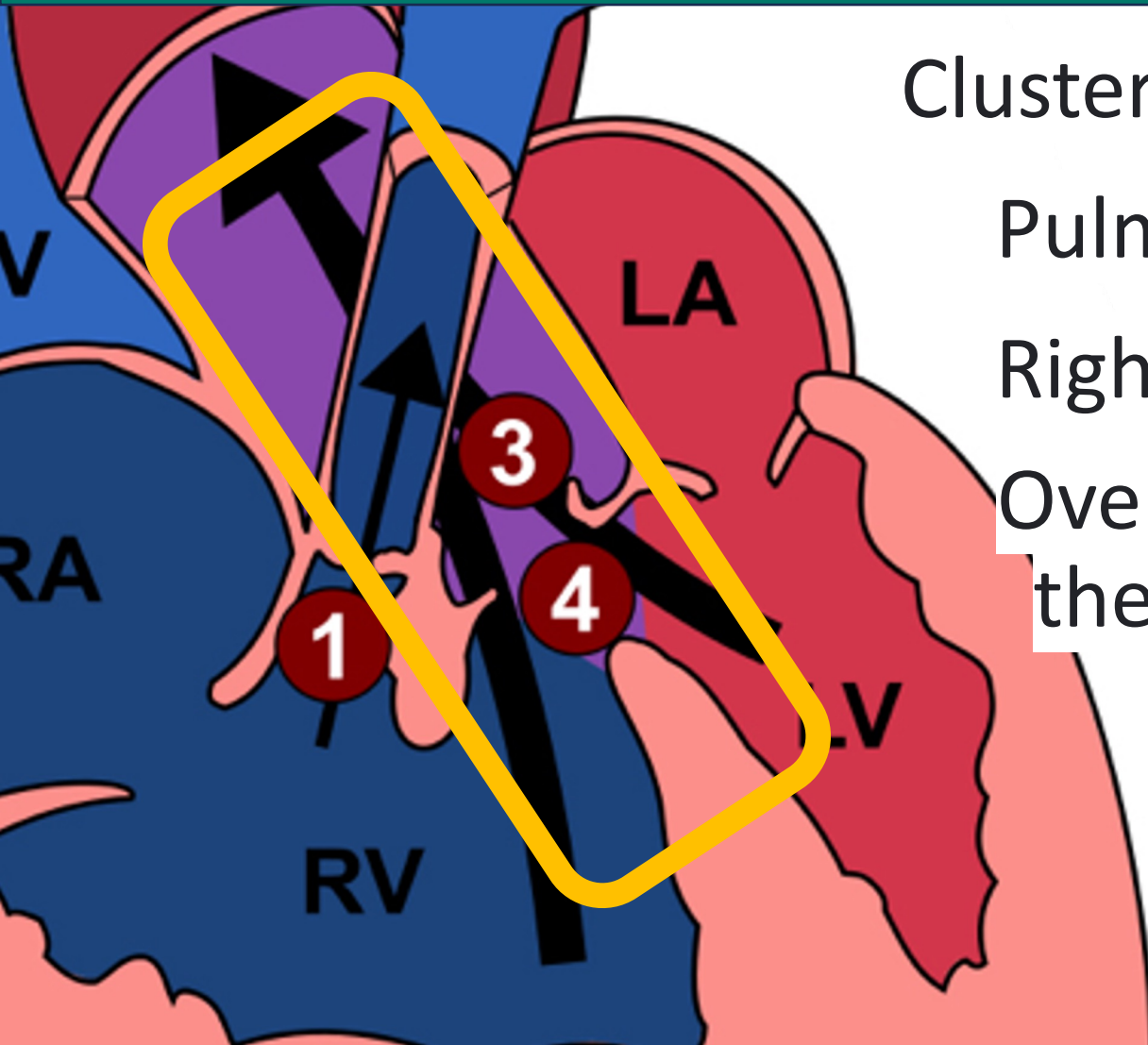


Cluster of 4 anomalies:

Pulmonary Stenosis

Right ventricular hypertrophy

Abnormal Connection: Tetralogy of Fallot



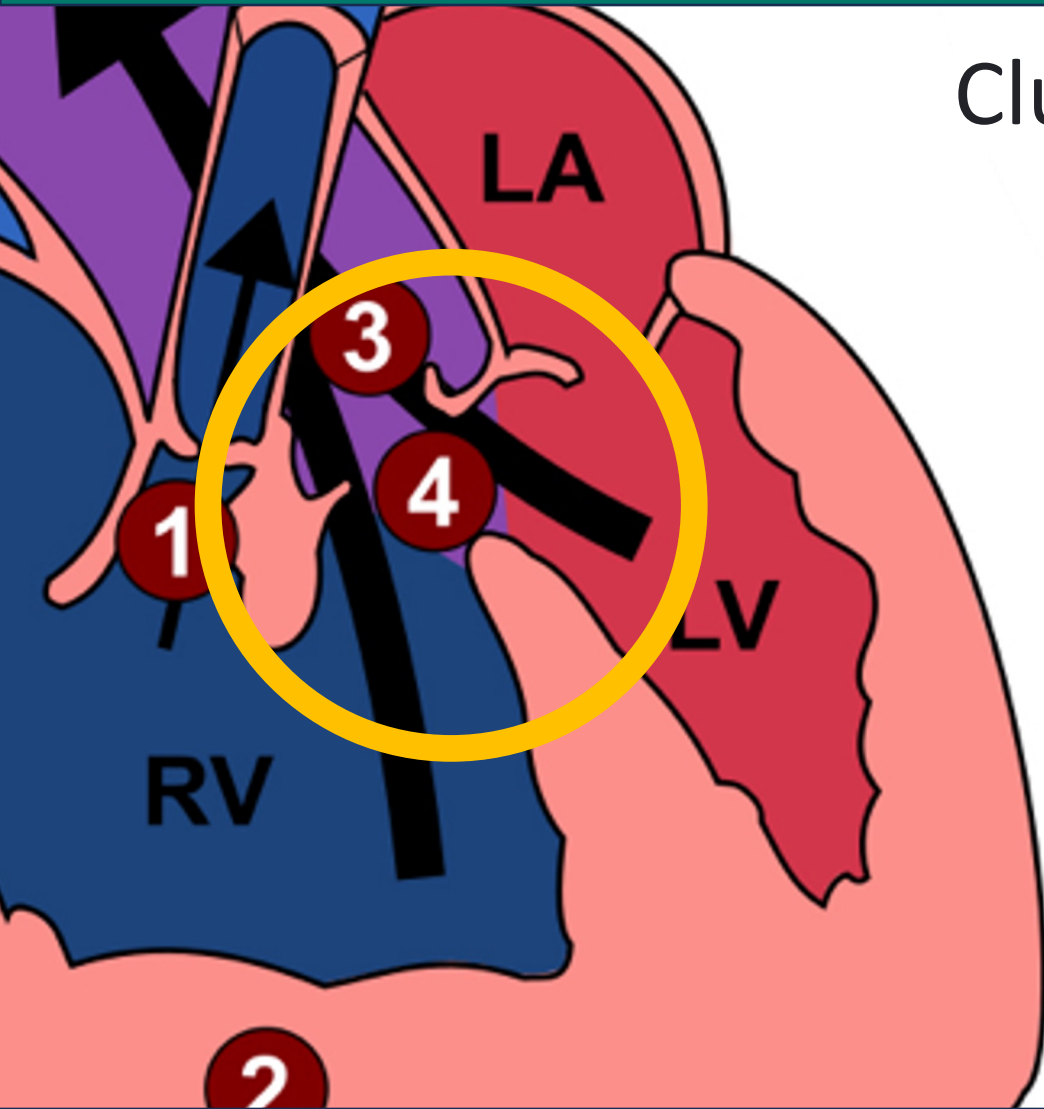
Cluster of 4 anomalies:

Pulmonary Stenosis

Right ventricular hypertrophy

Override of the ventricular septum by the aortic root

Abnormal Connection: Tetralogy of Fallot



Cluster of 4 anomalies:

Pulmonary Stenosis

Right ventricular hypertrophy

Override of the ventricular septum by the aortic root

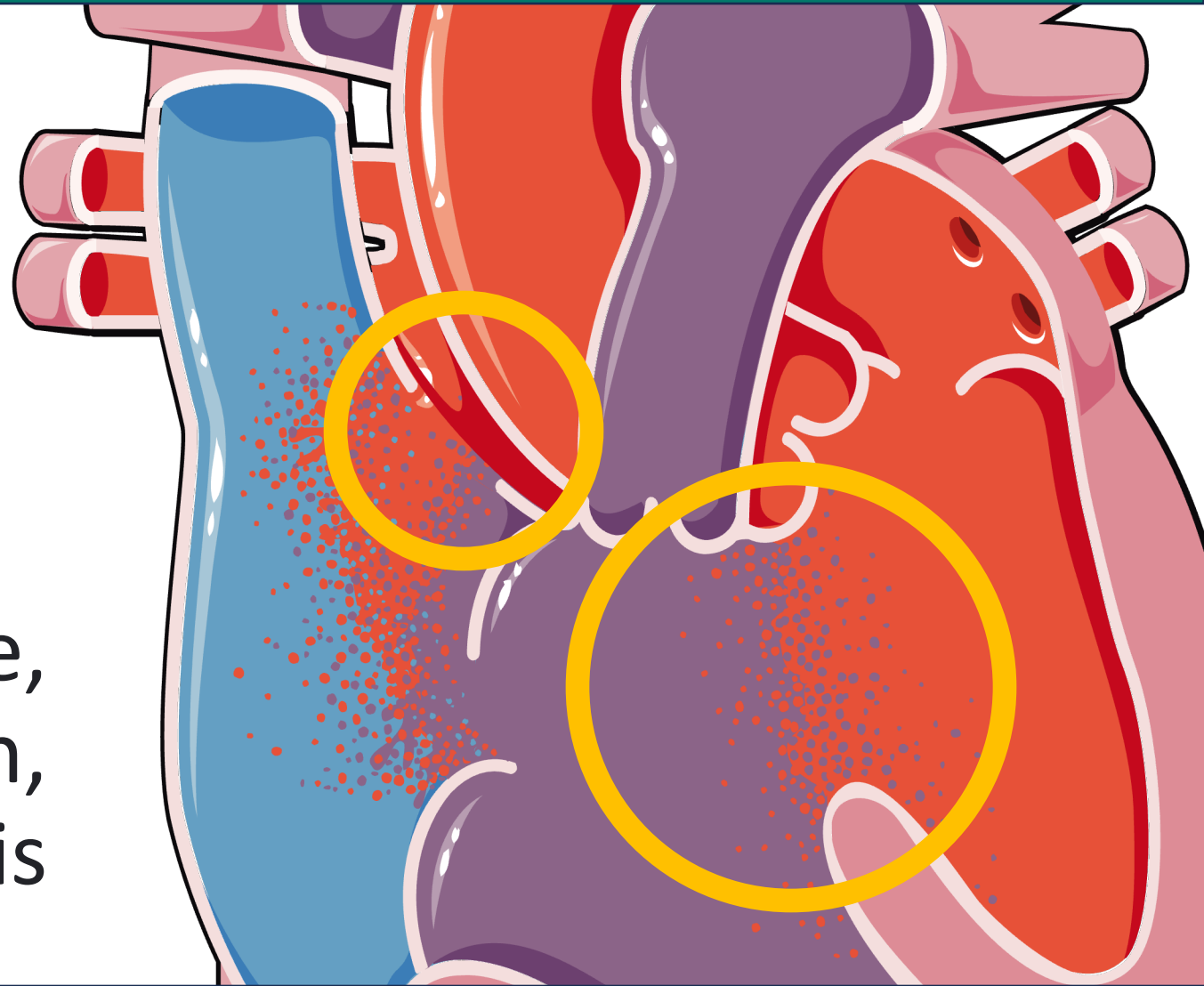
Ventricular septal defect

Q21.3 - ToF

Abnormal Conn: Atrioventricular Septal Defect

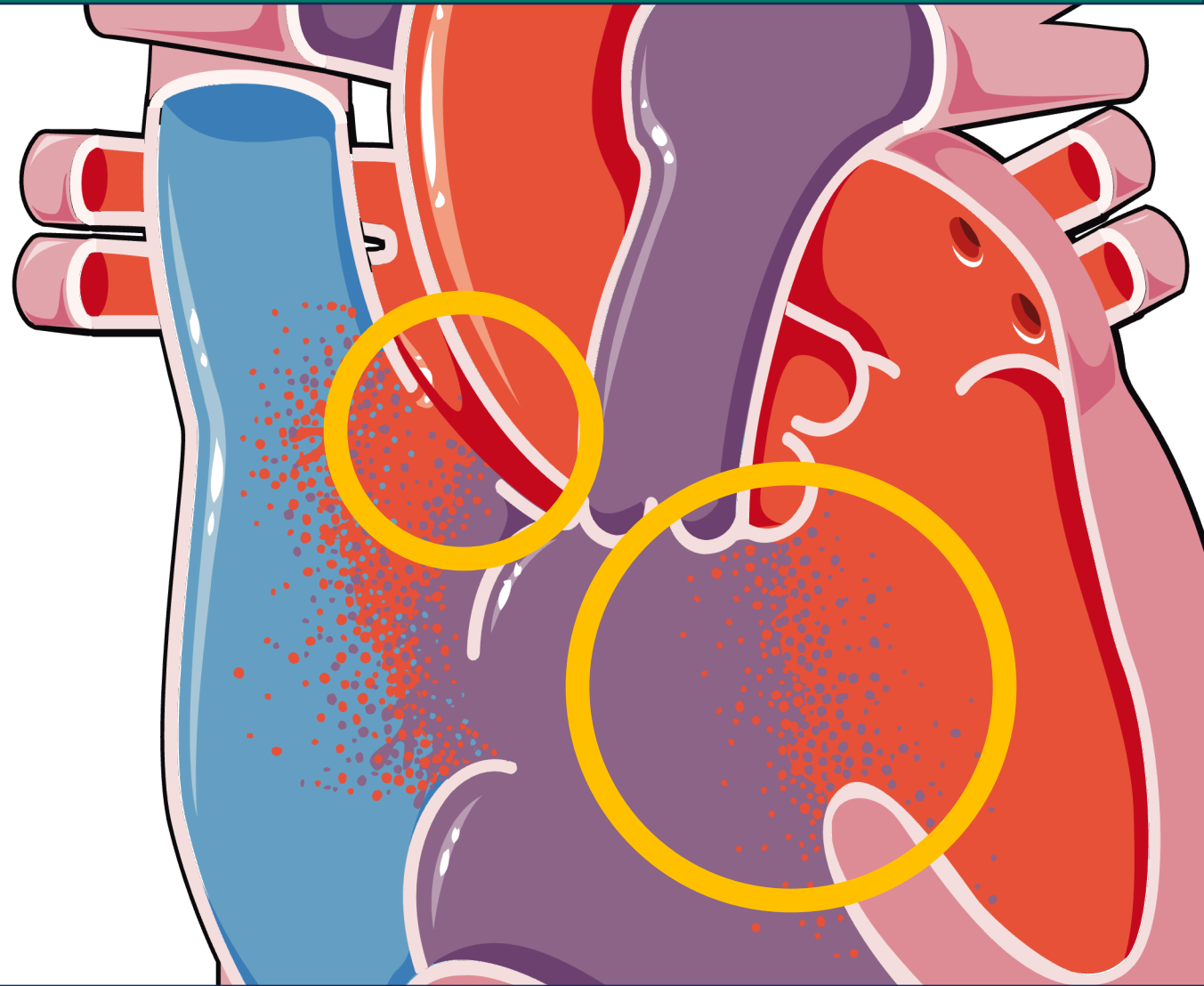
An opening or defect in the septum separating the two atria and the ventricles of the heart

Can lead to heart failure, pulmonary hypertension, and endocarditis

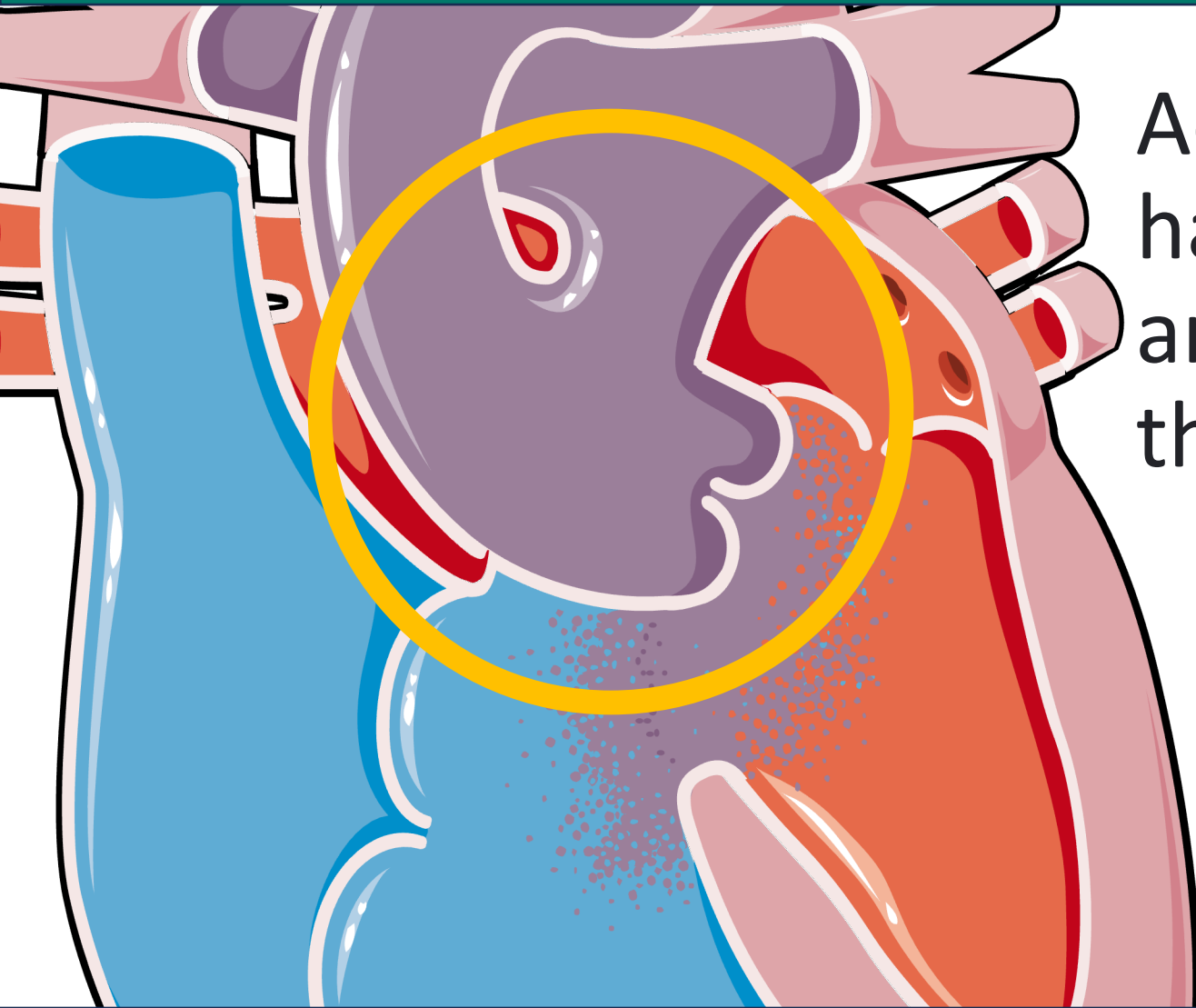


Abnormal Conn: Atrioventricular Septal Defect

- Q21.20 AVSD unsp, to partial or complete
- Q21.21 Partial AVSD
- Q21.22 Transitional AVSD
- Q21.23 Complete AVSD



Abnormal Connection: Truncus arteriosus



Aorta and pulmonary trunk have fused, creating a single arterial trunk arises from the heart

Repair consisting of: Separation of the Pulmonary Arteries, Closure of the Ventricular Septal Defect and Creation of a Right Ventricular Outflow Tract

Abnormal Conn: Hypoplastic Left Heart Syndrome

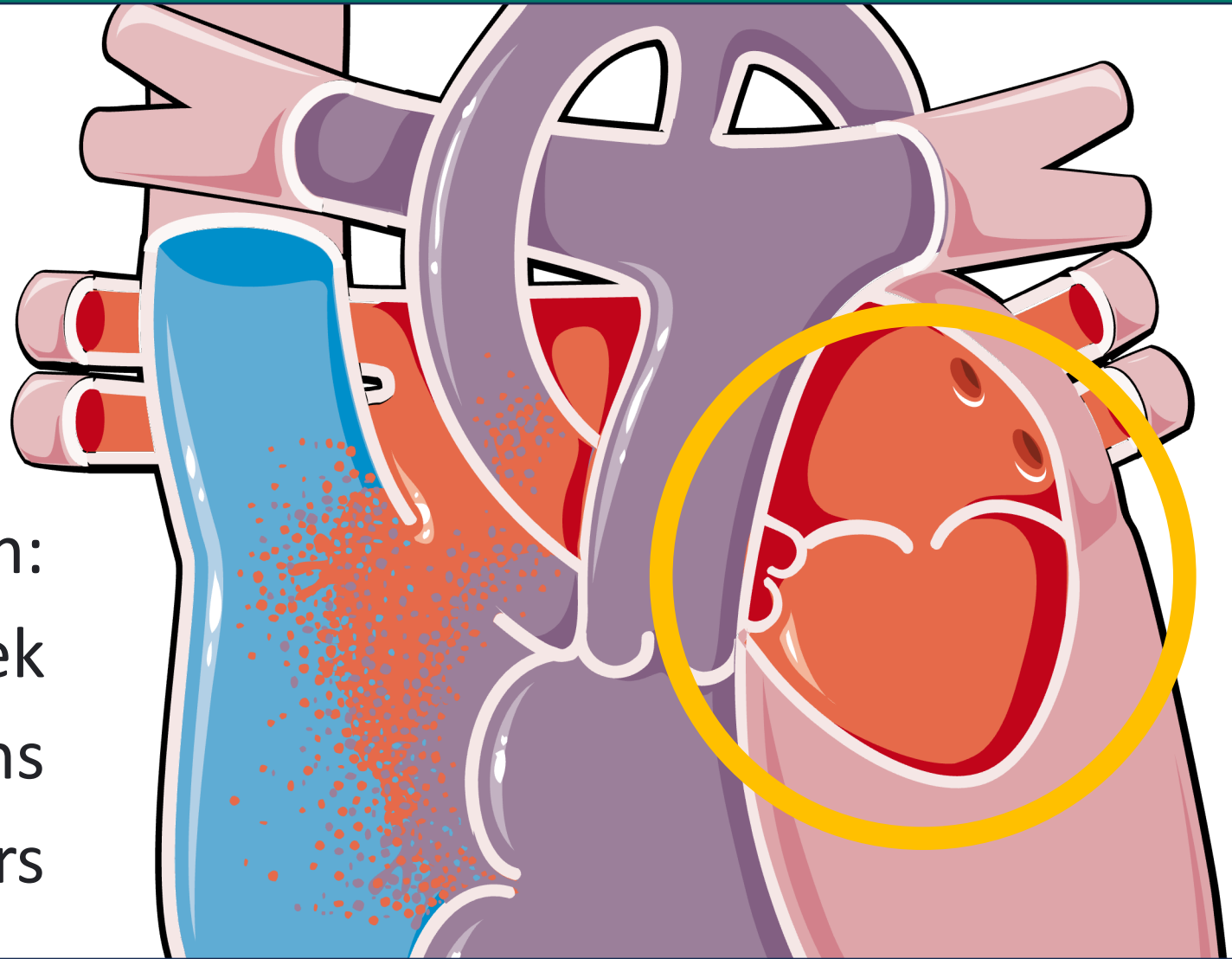
Underdevelopment
of the left-sided
structures of the heart

Cyanotic condition:

Norwood @ 1 week

Glenn @ 4-6 months

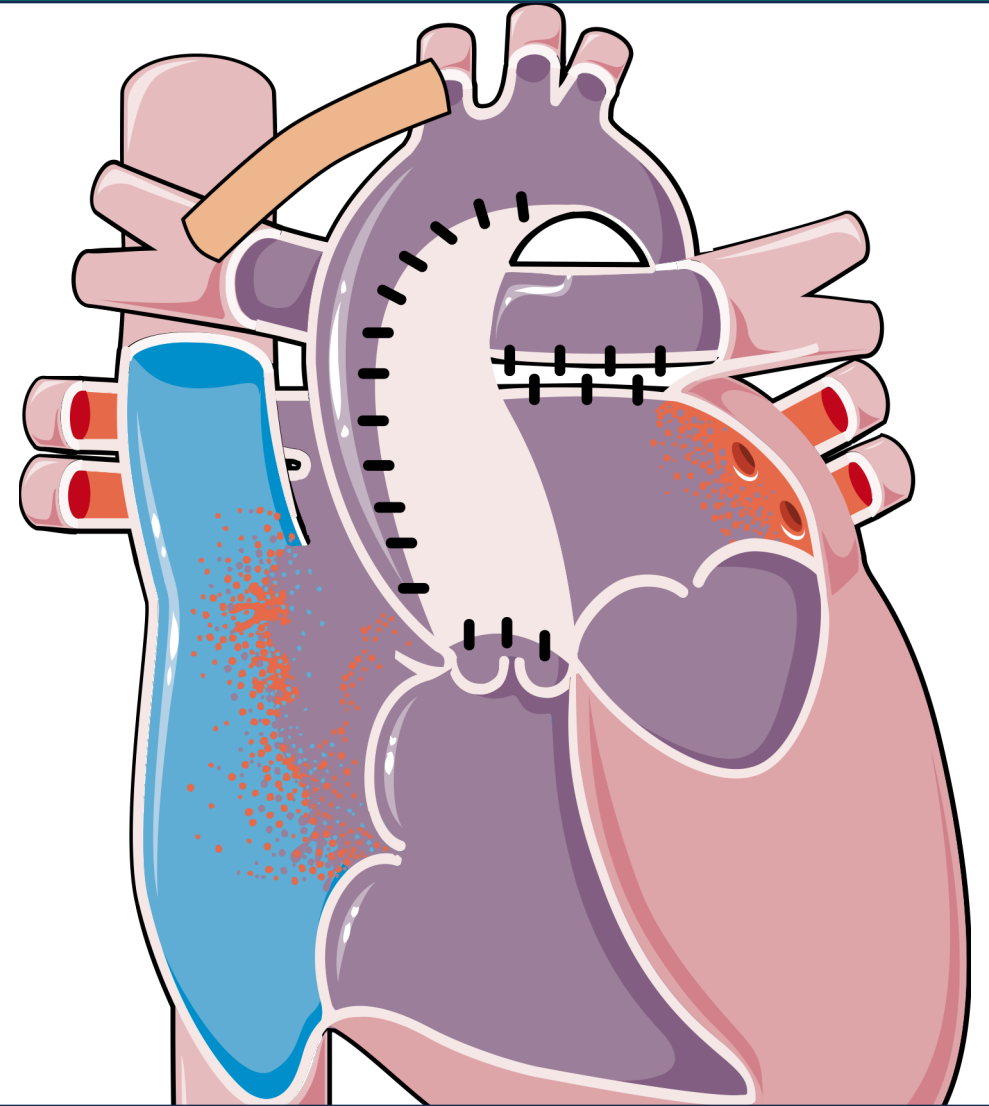
Fontan @ 18 months to 3 years



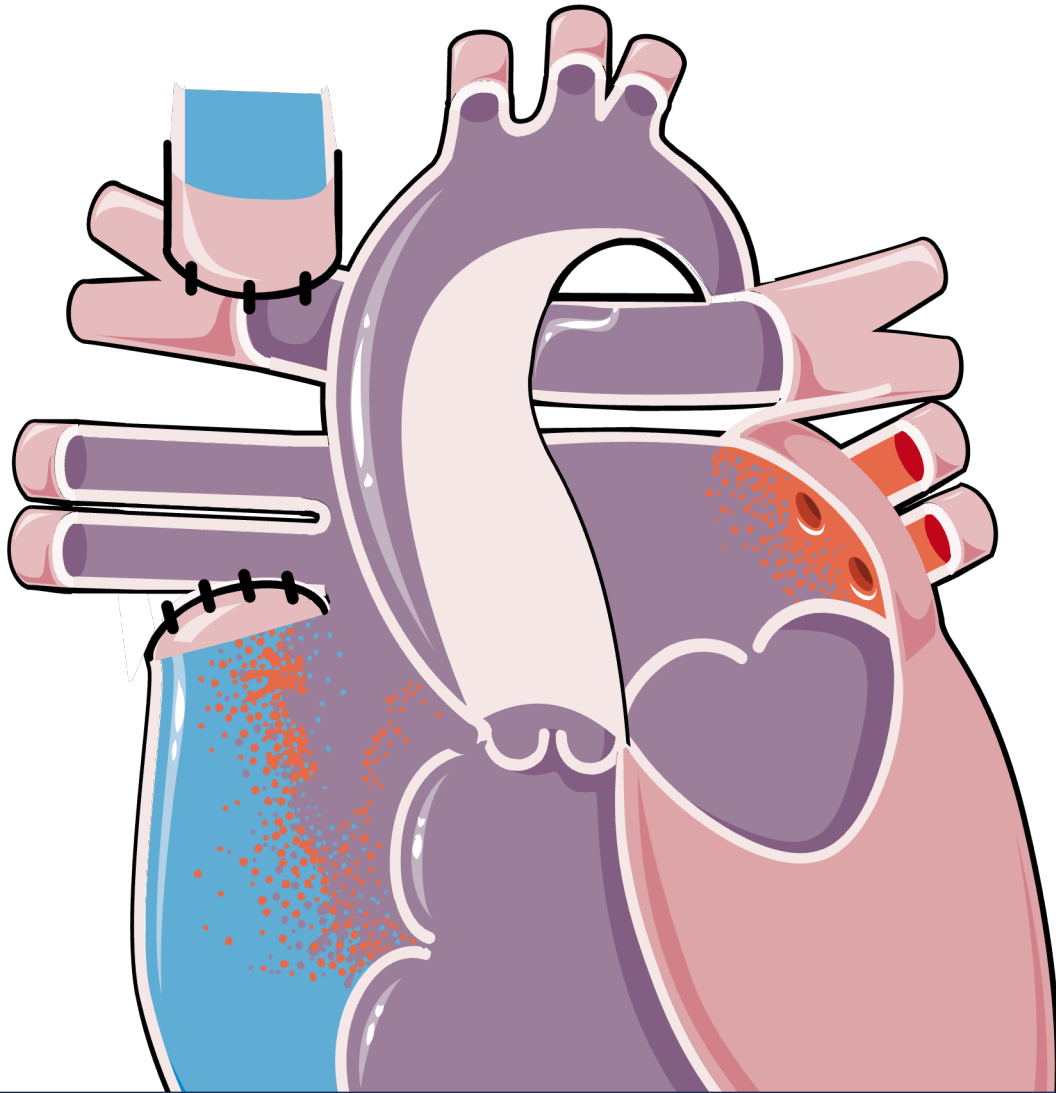
Stage 1: Norwood Procedure

The surgeon uses a patch and the pulmonary trunk to enlarge the aorta. Then, connects the new aorta to the right ventricle.

Second, a tube or shunt is placed between aorta and the pulmonary arteries.



Stage 2: Bidirectional Glenn procedure



The surgeon removes the shunt from the pulmonary artery.

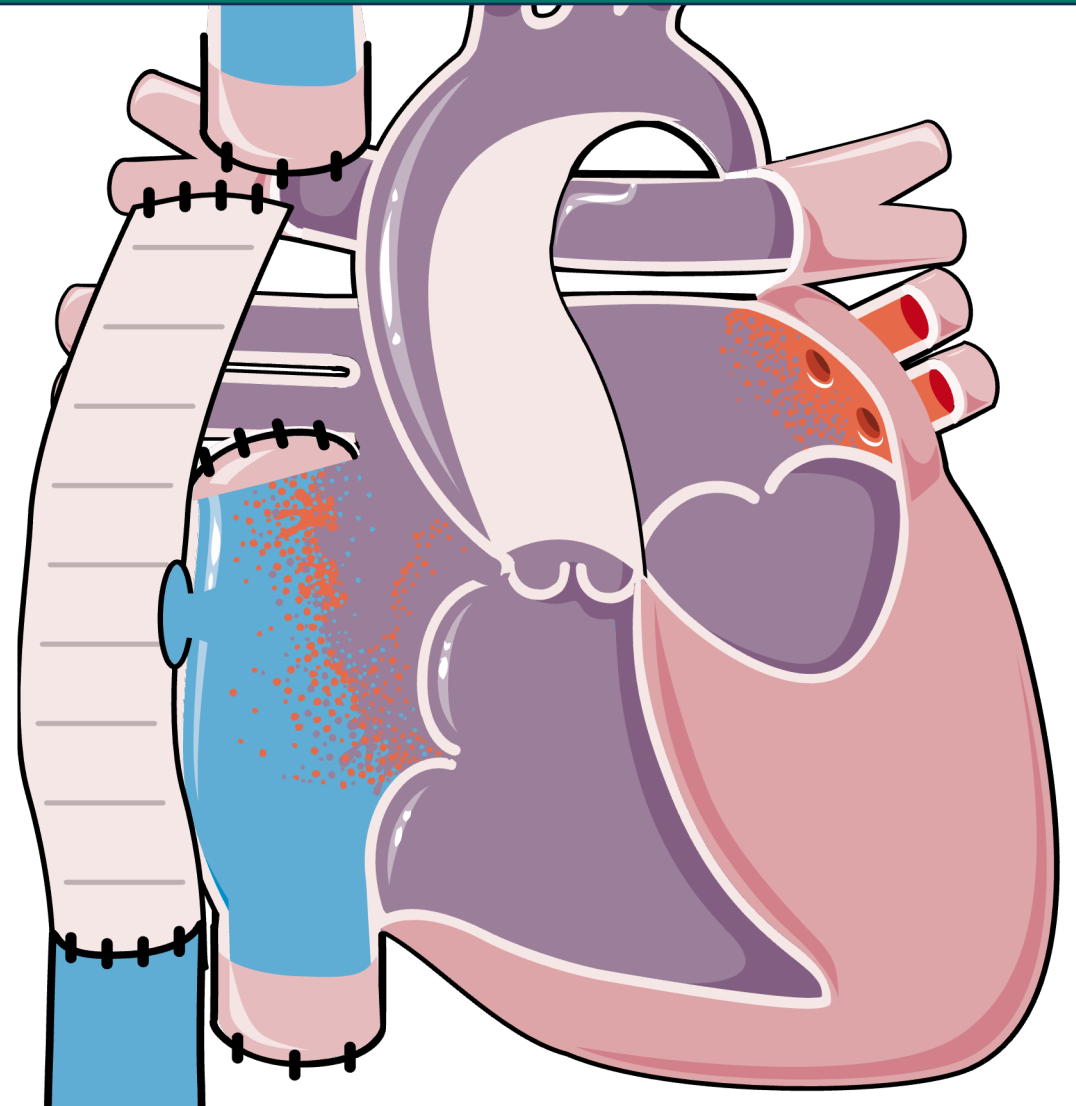
The superior vena cava is detached from the right atrium and attached to the pulmonary artery.

Stage 3: Fontan procedure

For the final procedure, the surgeon detaches the inferior vena cava.

Second, a tube or shunt is placed between inferior vena cava and the pulmonary arteries.

Finally, a fenestration is made between the conduit and right atrium (if appropriate).

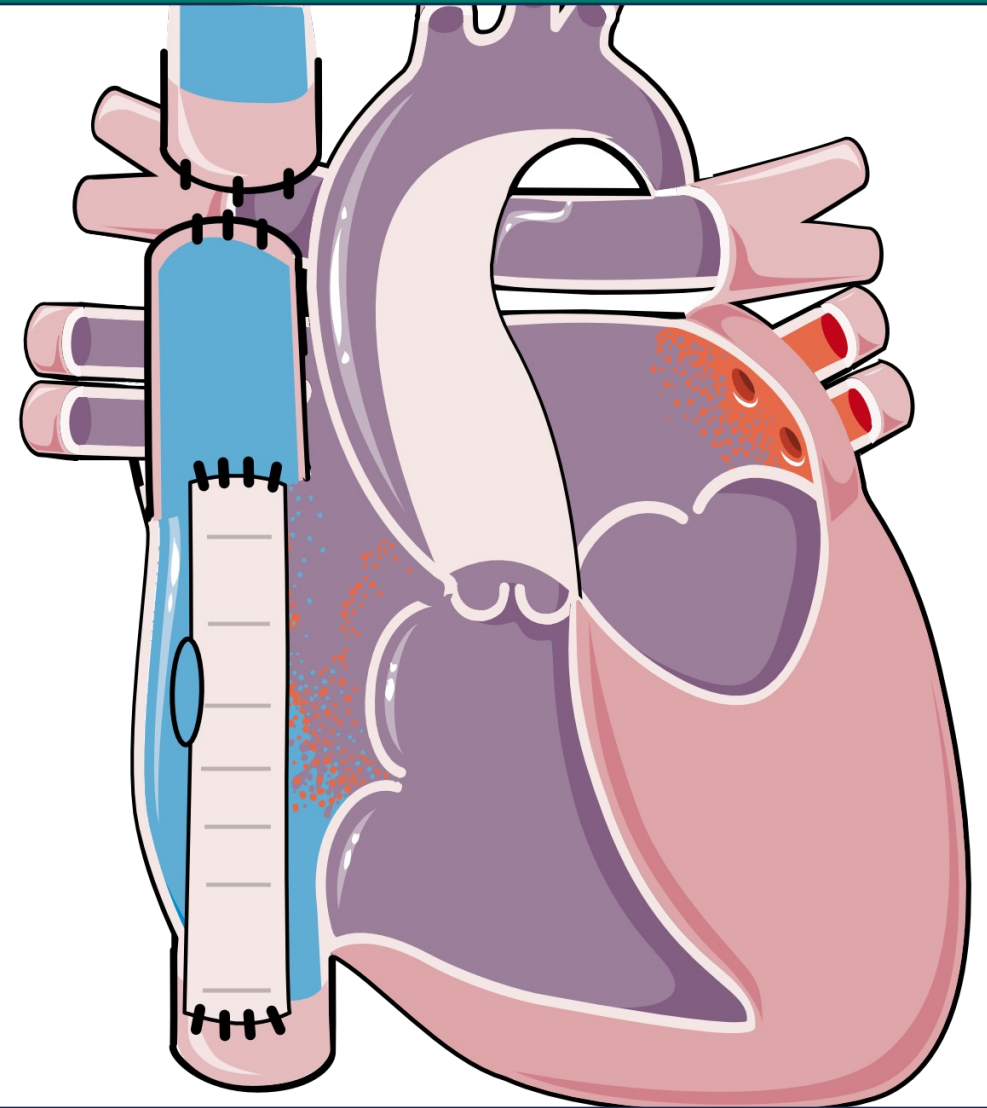


Stage 3: Fontan procedure

Alternately, the physician may do an intracardiac Fontan, also known as Lateral Funnel Fontan.

Second, a tube or shunt is placed between inferior vena cava and the superior vena cava.

Finally, a fenestration is made between the conduit and right atrium.



INTRACARDIAC FONTAN (LATERAL FUNNEL FONTAN)

Question

True or False?

Normal connections are acyanotic,
while Abnormal connections are
cyanotic.

Answer

Normal connections where the blood normally flows through the circulatory system.

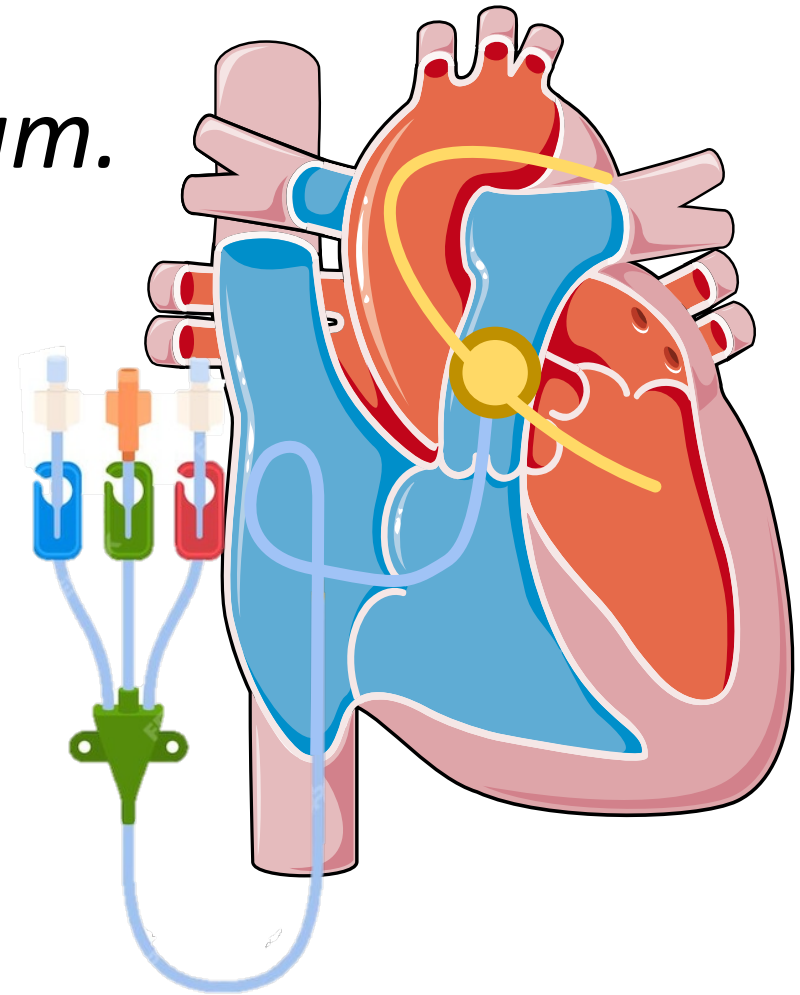
Abnormal connections have a mixing of deoxygenated blood resulting in a reduction of oxygen to the rest of the body.

Heart cath involves 2 things

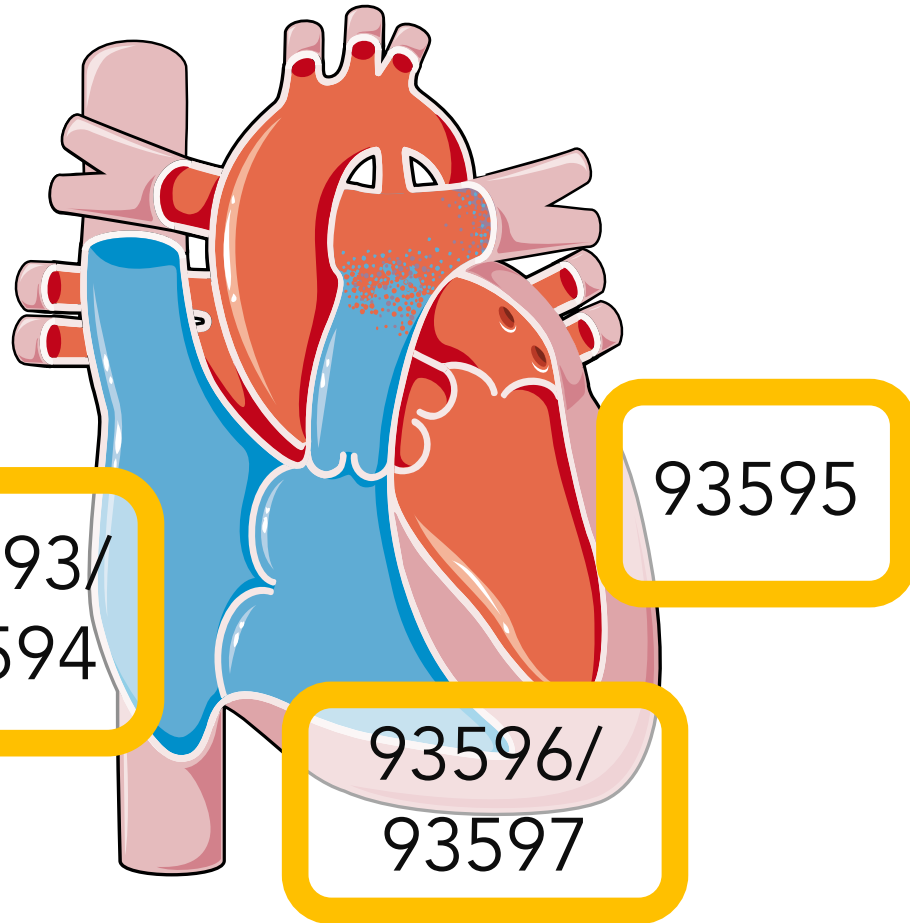
Catheter into a *ventricle* or *atrium*.

Performing *hemodynamic measurements*:

- Intracardiac pressure measurements
- Oxygen saturation
- Cardiac output



Normal vs Abnormal Connections

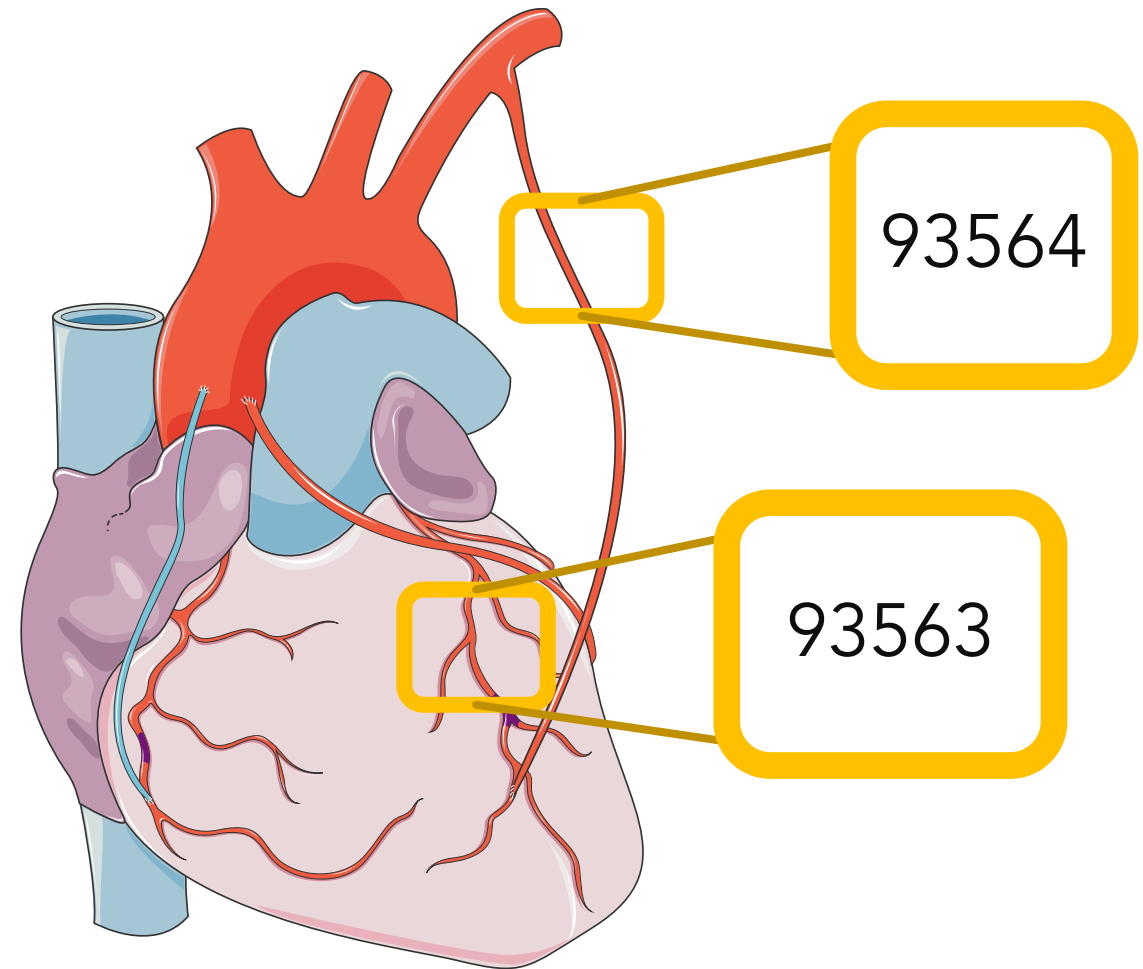


Patent ductus arteriosus

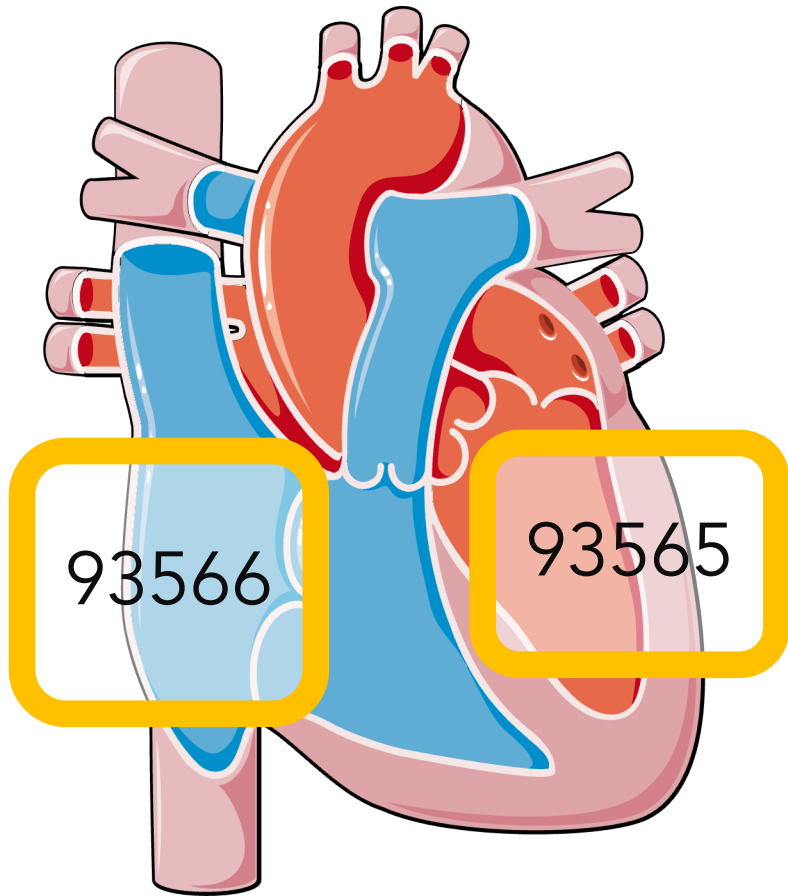
Side	Normal Connection	Abnormal Connection
Right Heart Only	93593	93594
Left Heart Only	93595	93595
Right and Left Heart	93596	93597

Add-On Codes: Report Separately

	Congenital Codes
Coronary Angiogram	93563
Bypass Artery Angiogram	93564

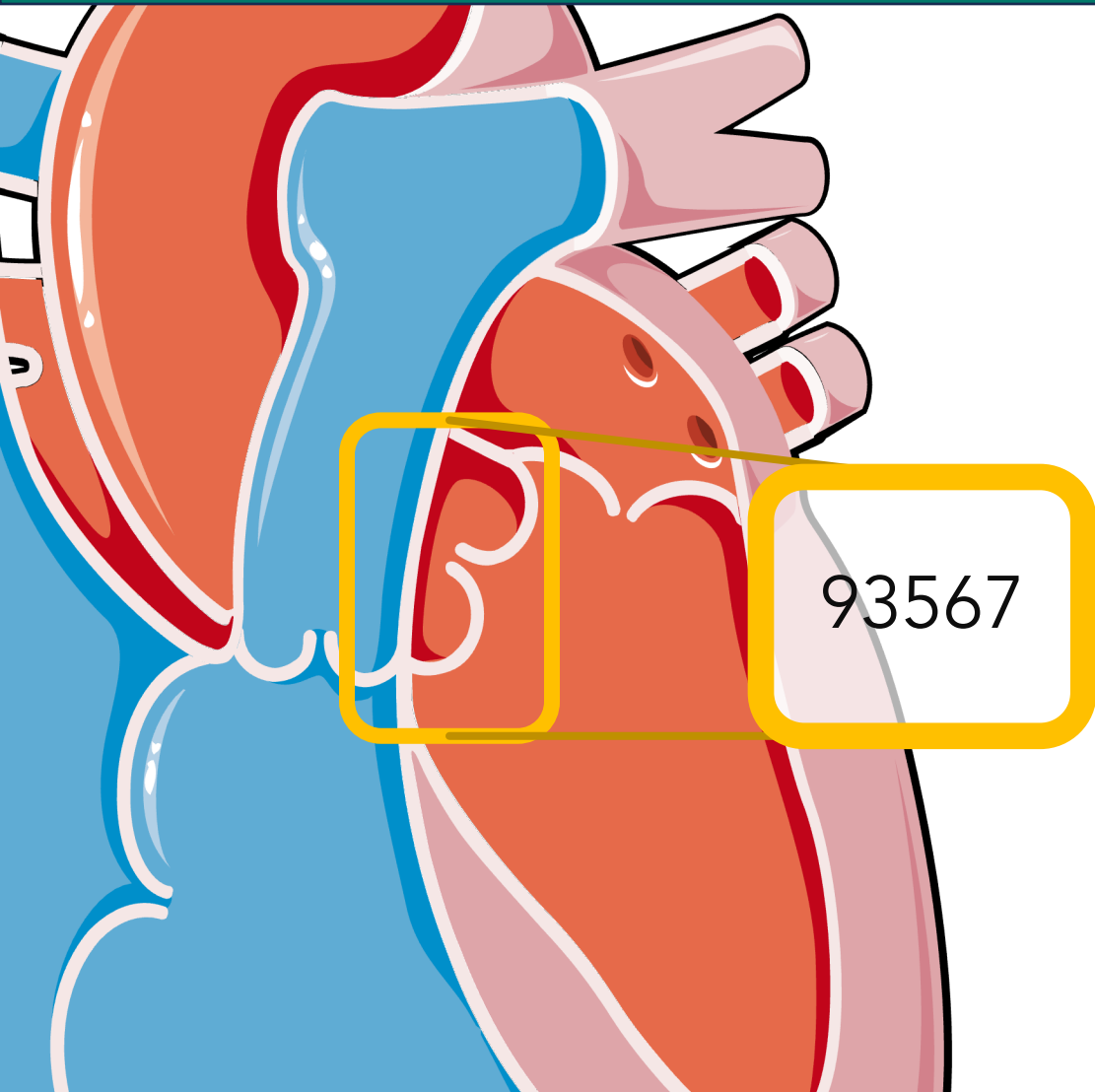


Angiogram Add-on codes



	Congenital Codes
Left ventricular or atrium angiography	93565
Right ventricular or atrium angiography	93566
Supravalvular aortography	93567

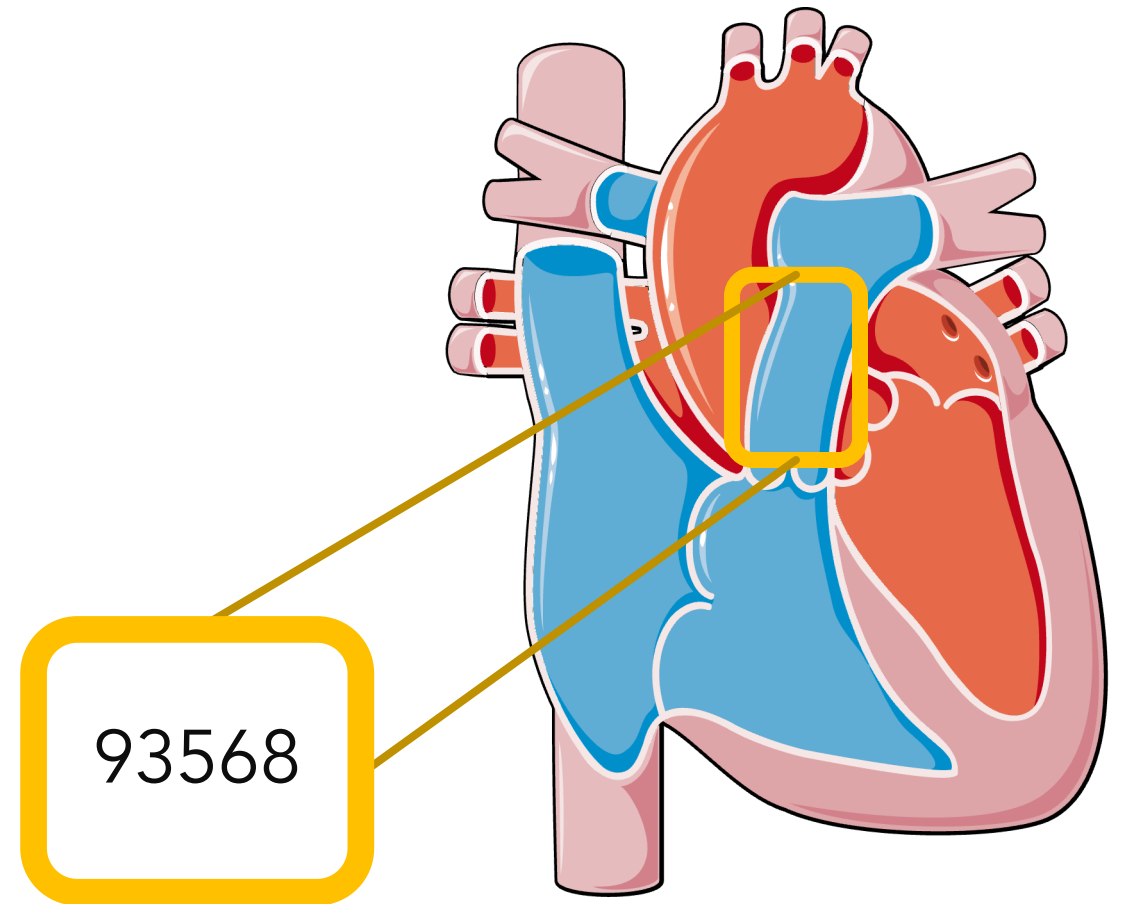
Angiogram Add-on codes



	Congenital Codes
Left ventricular or atrium angiography	93565
Right ventricular or atrium angiography	93566
Supravalvular aortography	93567

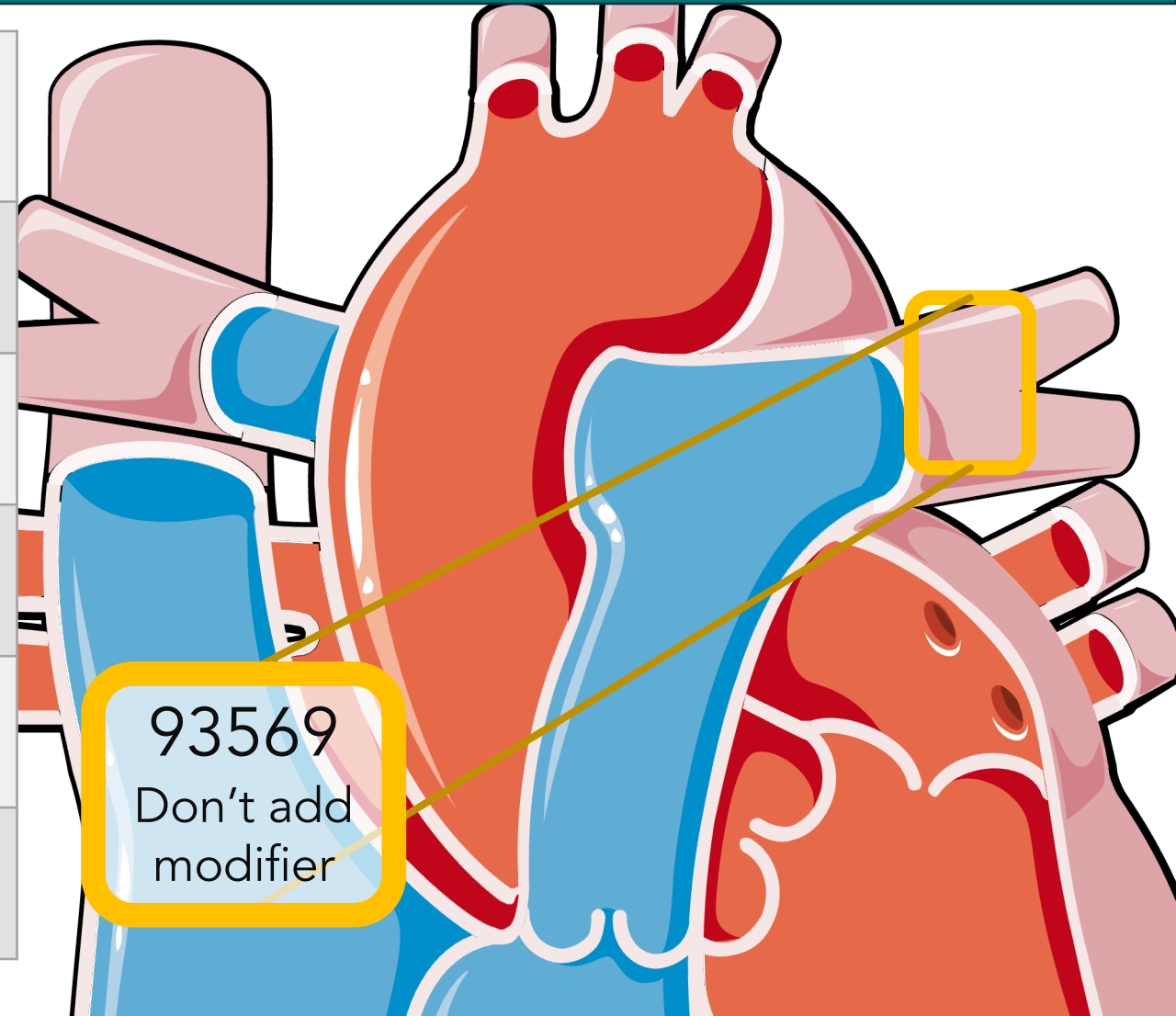
Pulmonary Angiograms

	Congenital Codes
Non-Selective Pulmonary	93568
Unilateral, Pulmonary	93569
Bilateral, Pulmonary	93573
Pulmonary Vein (MUE 4)	93574
Major aortopulmonary collateral artery: MAPCA (MUE 10)	93575



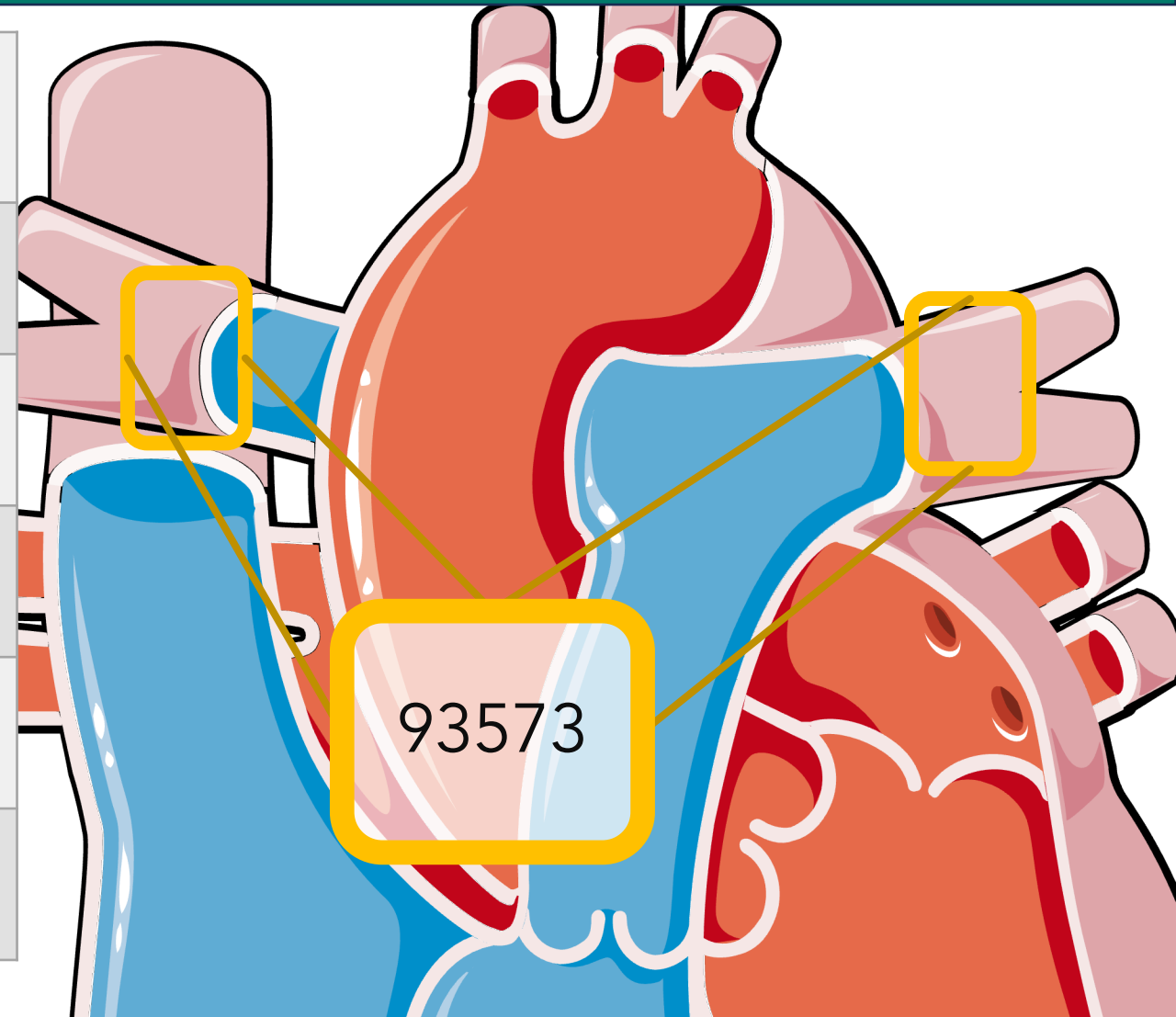
Pulmonary Angiograms

	Congenital Codes
Non-Selective Pulmonary	93568
Unilateral, Pulmonary	93569
Bilateral, Pulmonary	93573
Pulmonary Vein (MUE 4)	93574
Major aortopulmonary collateral artery: MAPCA (MUE 10)	93575



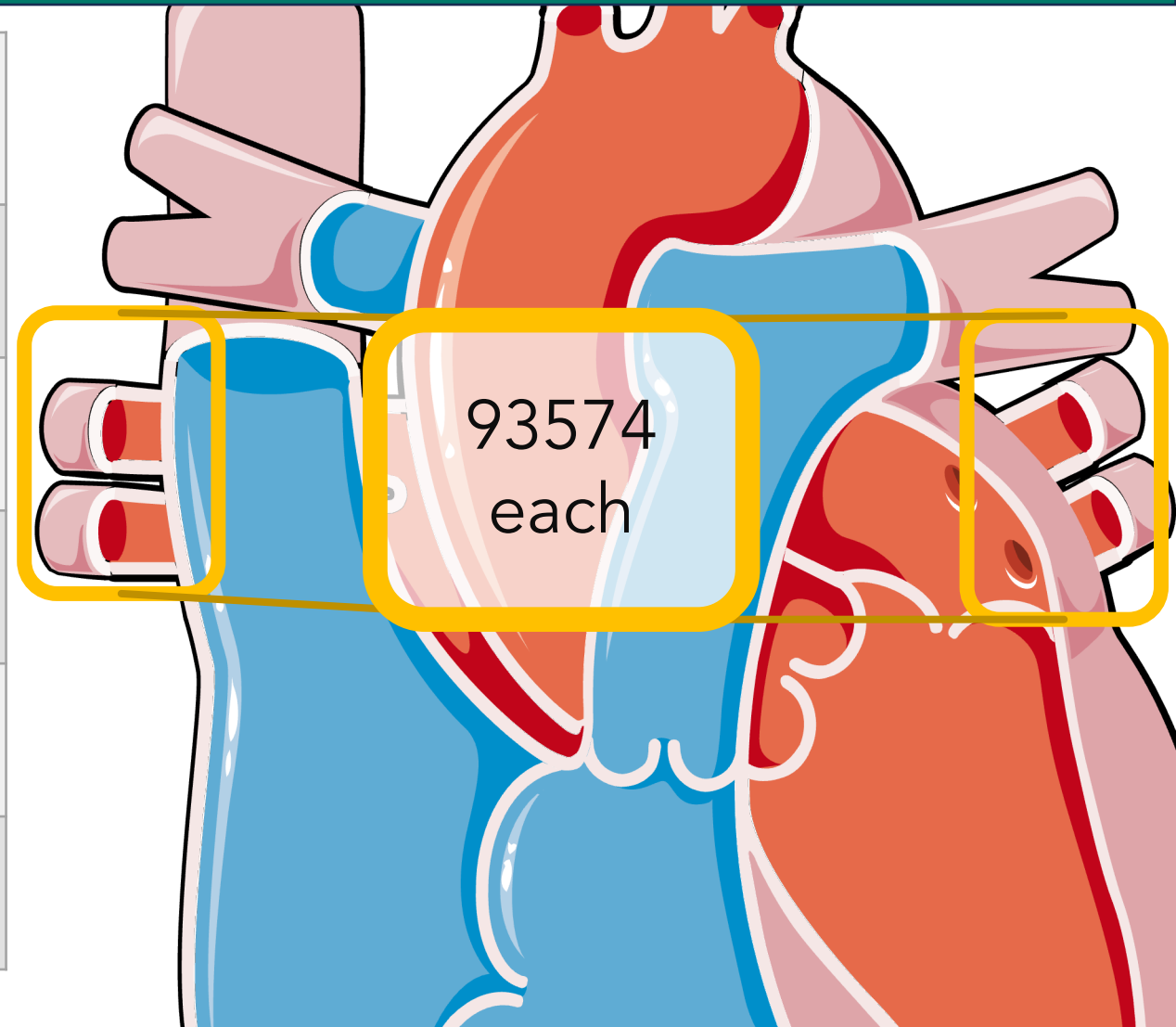
Pulmonary Angiograms

	Congenital Codes
Non-Selective Pulmonary	93568
Unilateral, Pulmonary	93569
Bilateral, Pulmonary	93573
Pulmonary Vein (MUE 4)	93574
Major aortopulmonary collateral artery: MAPCA (MUE 10)	93575



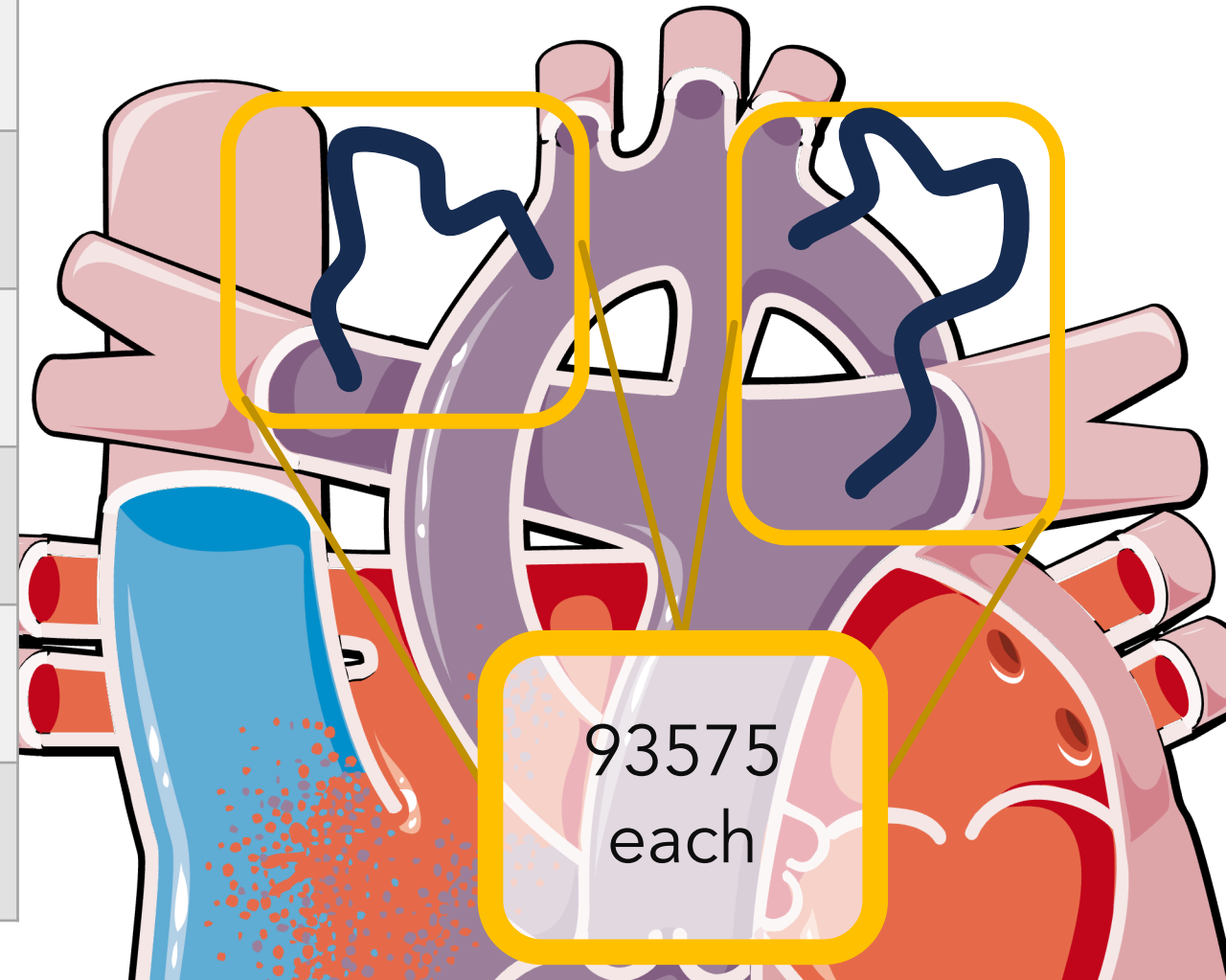
Pulmonary Angiograms

	Congenital Codes
Non-Selective Pulmonary	93568
Unilateral, Pulmonary	93569
Bilateral, Pulmonary	93573
Pulmonary Vein (MUE 4)	93574
Major aortopulmonary collateral artery: MAPCA (MUE 10)	93575

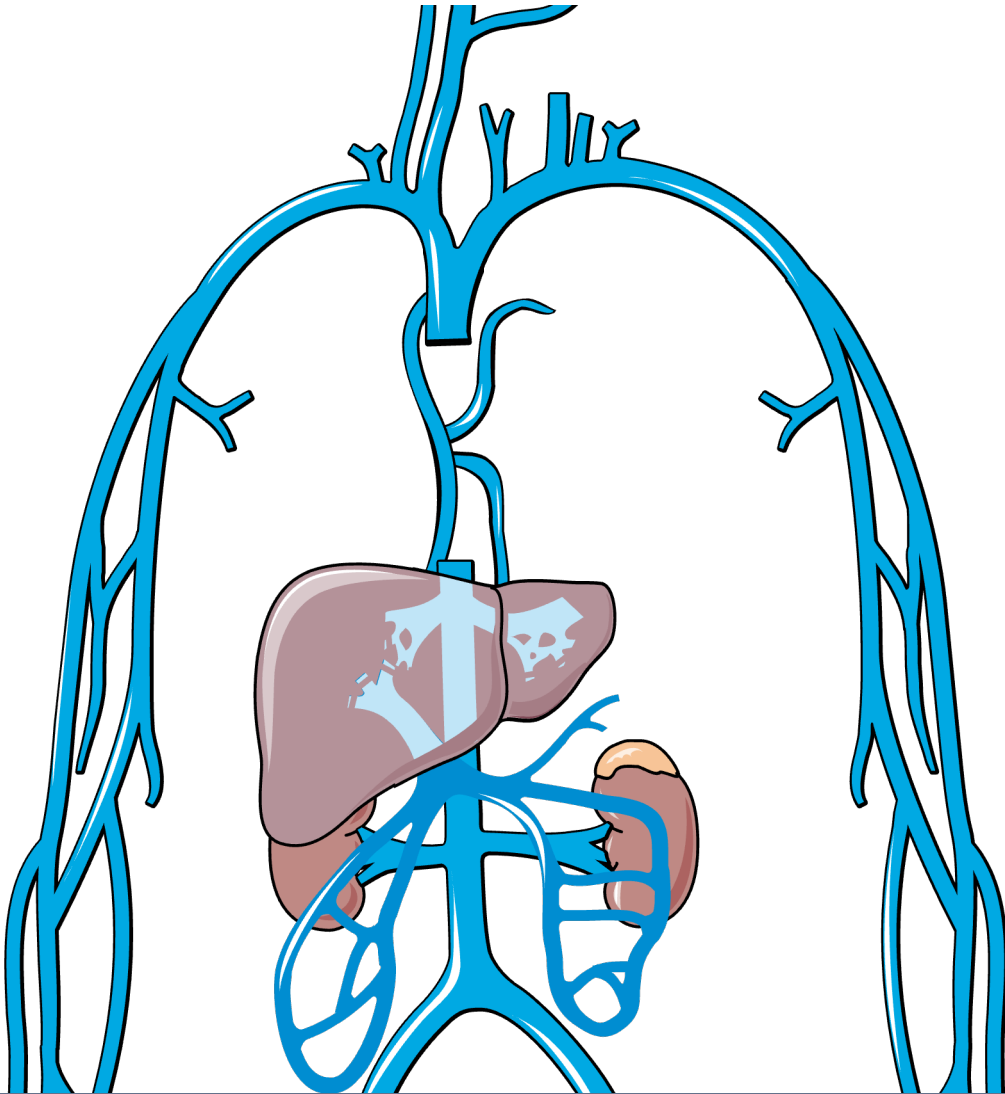


Pulmonary Angiograms

	Congenital Codes
Non-Selective Pulmonary	93568
Unilateral, Pulmonary	93569
Bilateral, Pulmonary	93573
Pulmonary Vein (MUE 4)	93574
Major aortopulmonary collateral artery: MAPCA (MUE 10)	93575

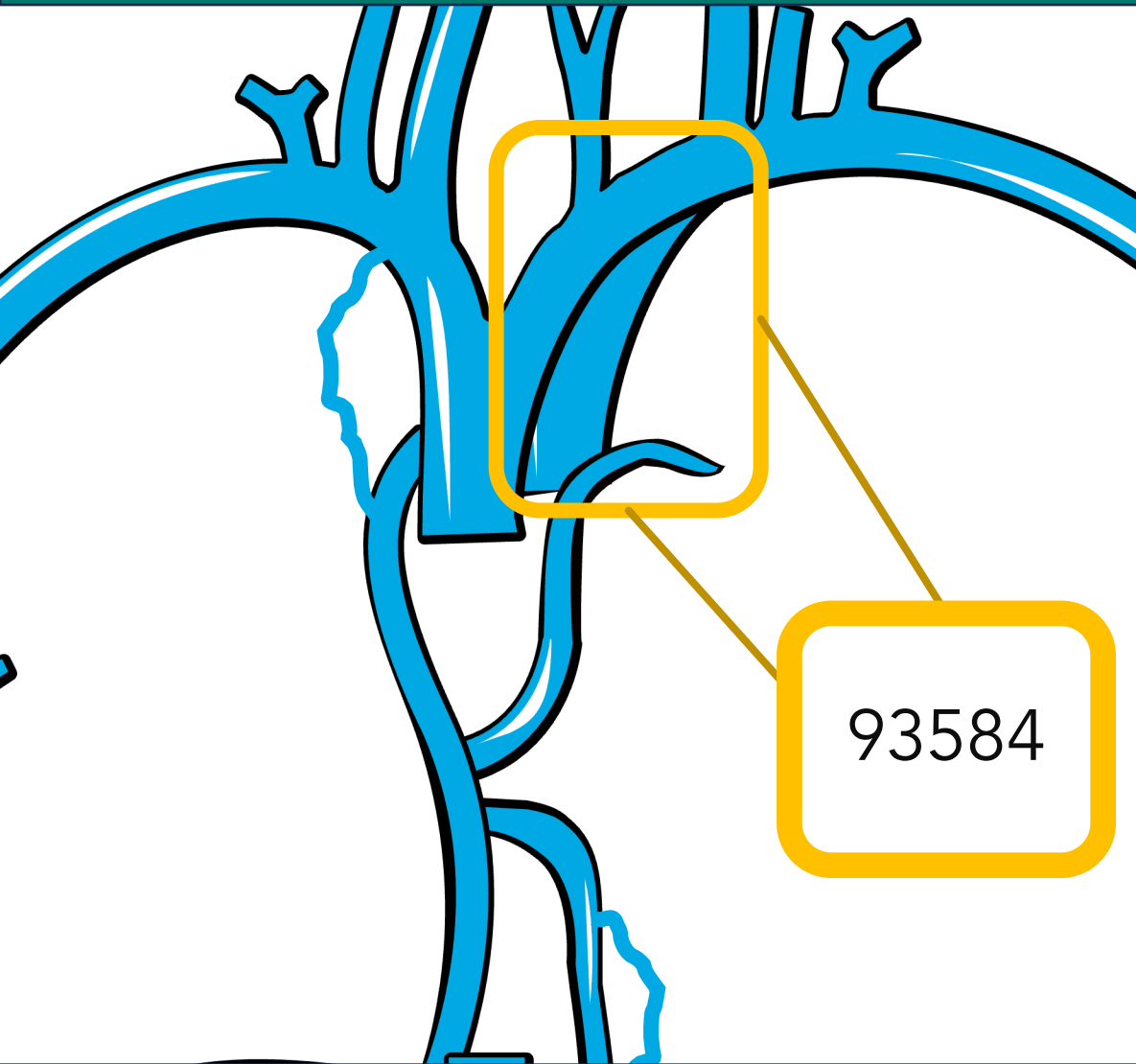


Venous Add-on codes



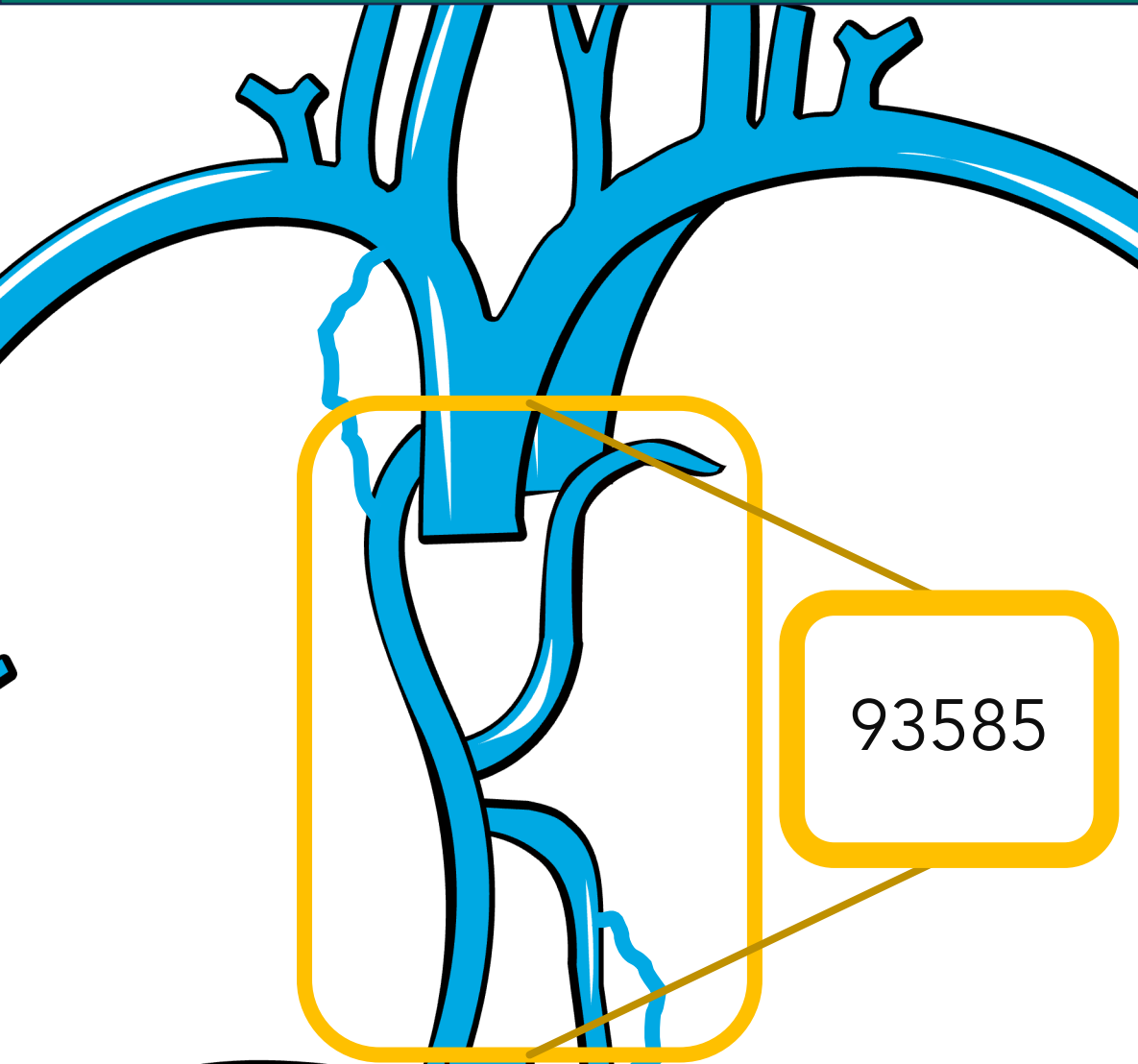
	Congenital Codes
Superior Vena Cava	75827
Inferior Vena Cava	75825
Second SVC imaging (after 75827)	93584
Azygos/hemiazygos venography	93585
Coronary sinus venogram	93586
Veno-venous collateral (at or <i>above</i> the heart)	93587
Veno-venous collateral venography below the heart	93588

Venous Add-on codes



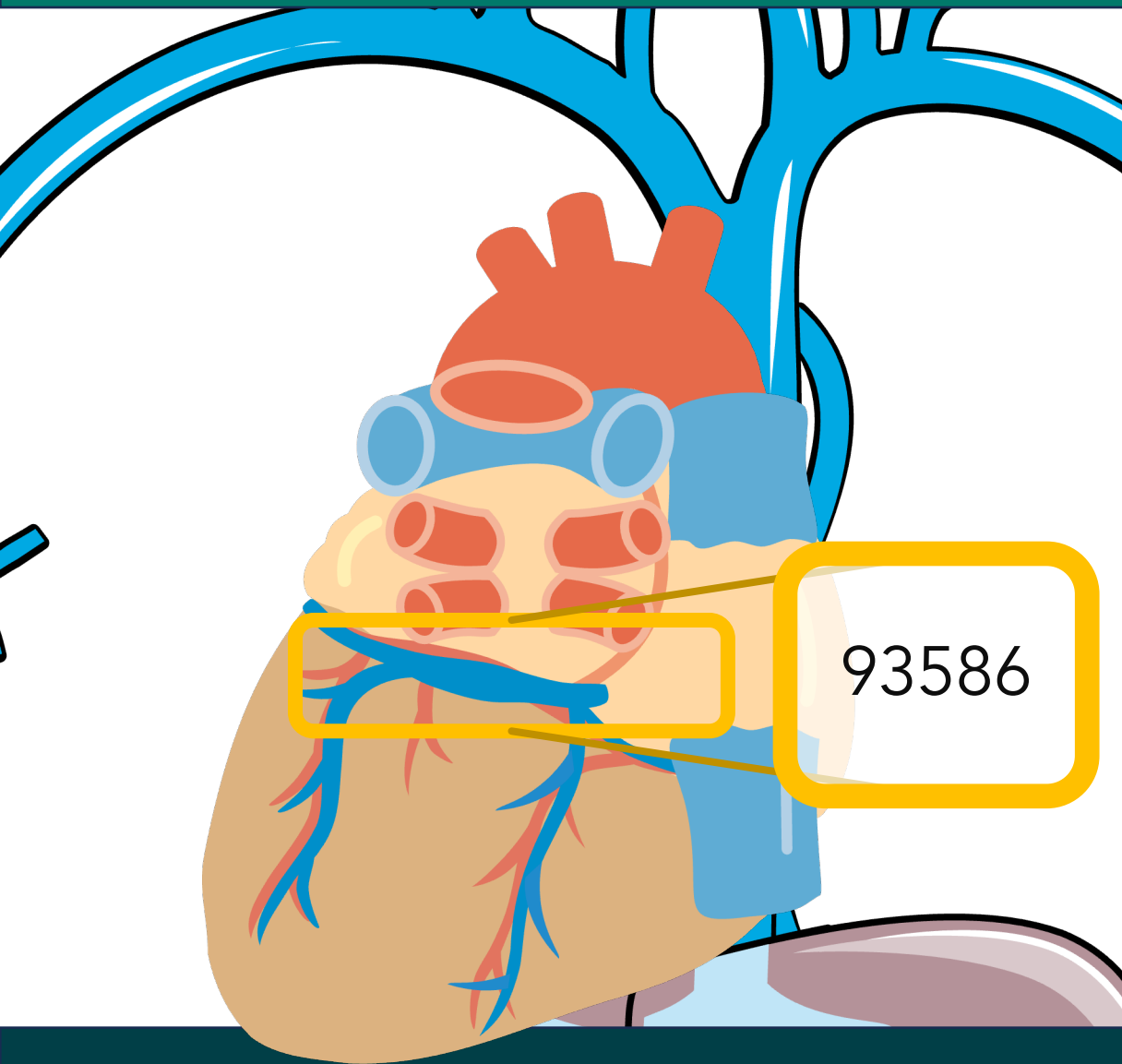
	Congenital Codes
Superior Vena Cava	75827
Inferior Vena Cava	75825
Second SVC imaging (after 75827)	93584
Azygos/hemiazygos venography	93585
Coronary sinus venogram	93586
Veno-venous collateral (at or <i>above</i> the heart)	93587
Veno-venous collateral venography below the heart	93588

Venous Add-on codes



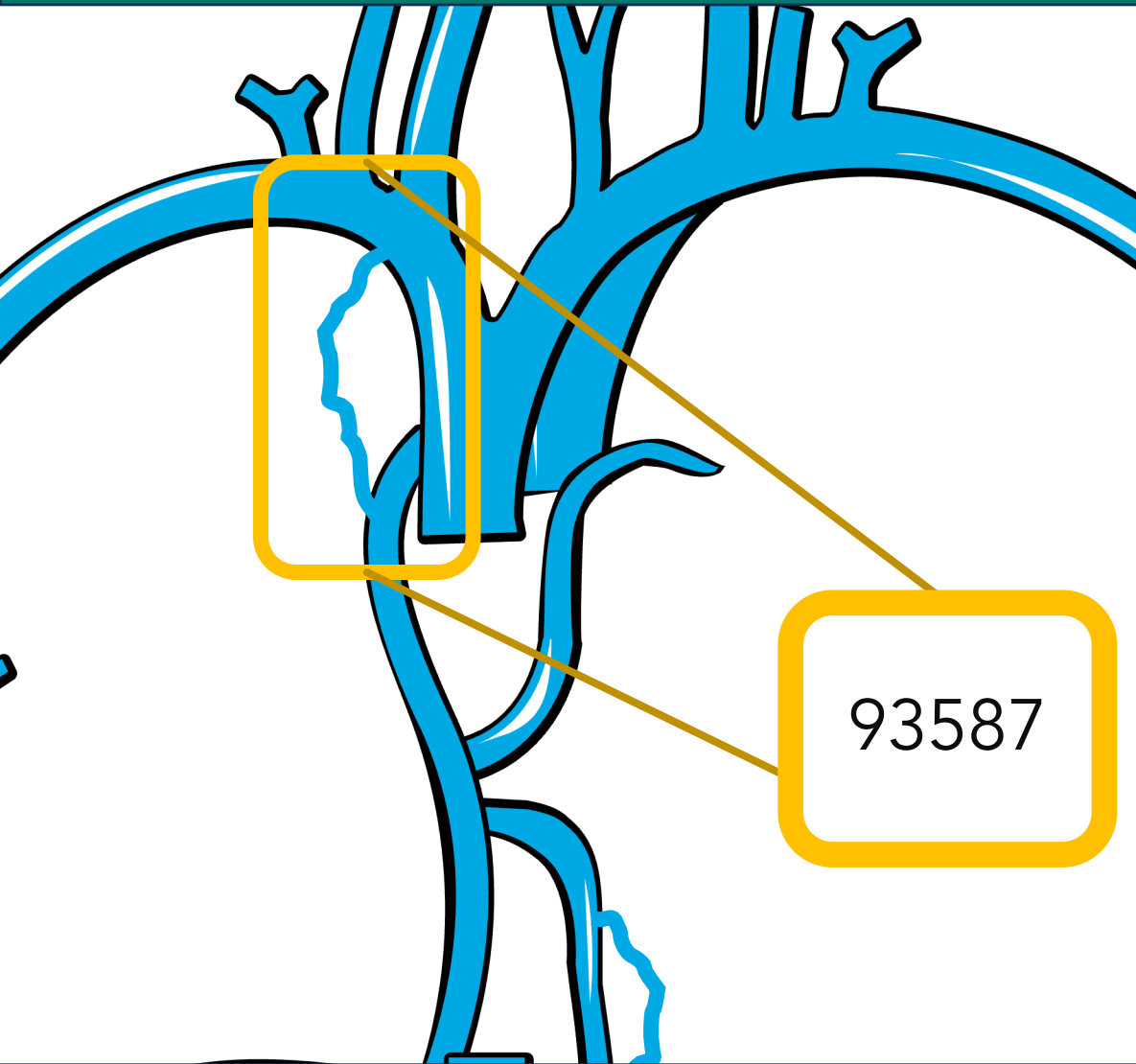
	Congenital Codes
Superior Vena Cava	75827
Inferior Vena Cava	75825
Second SVC imaging (after 75827)	93584
Azygos/hemiazygos venography	93585
Coronary sinus venogram	93586
Veno-venous collateral (at or <i>above</i> the heart)	93587
Veno-venous collateral venography below the heart	93588

Venous Add-on codes



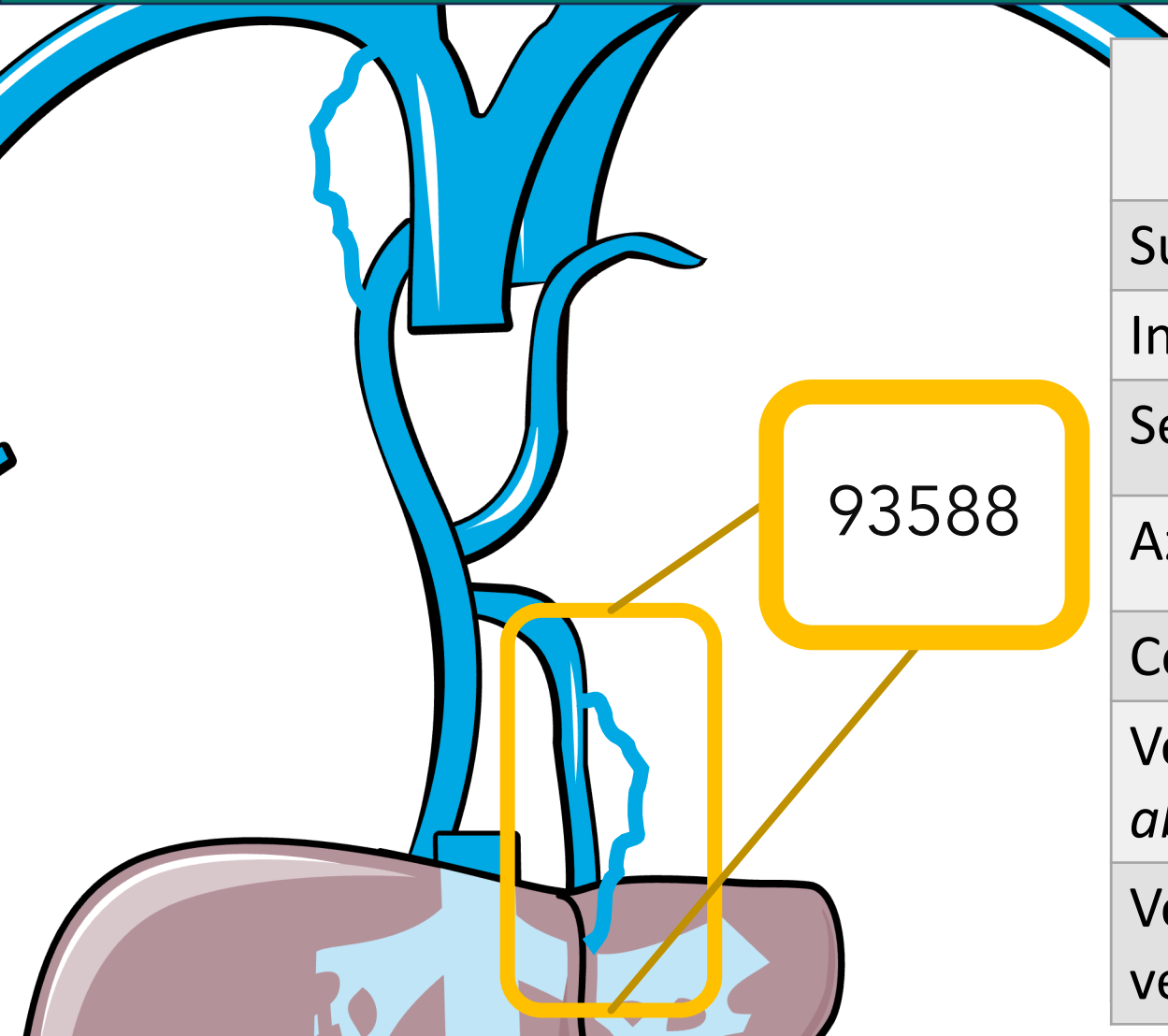
	Congenital Codes
Superior Vena Cava	75827
Inferior Vena Cava	75825
Second SVC imaging (after 75827)	93584
Azygos/hemiazygos venography	93585
Coronary sinus venogram	93586
Veno-venous collateral (at or <i>above</i> the heart)	93587
Veno-venous collateral venography below the heart	93588

Venous Add-on codes



	Congenital Codes
Superior Vena Cava	75827
Inferior Vena Cava	75825
Second SVC imaging (after 75827)	93584
Azygos/hemiazygos venography	93585
Coronary sinus venogram	93586
Veno-venous collateral (at or <i>above</i> the heart)	93587
Veno-venous collateral venography below the heart	93588

Venous Add-on codes

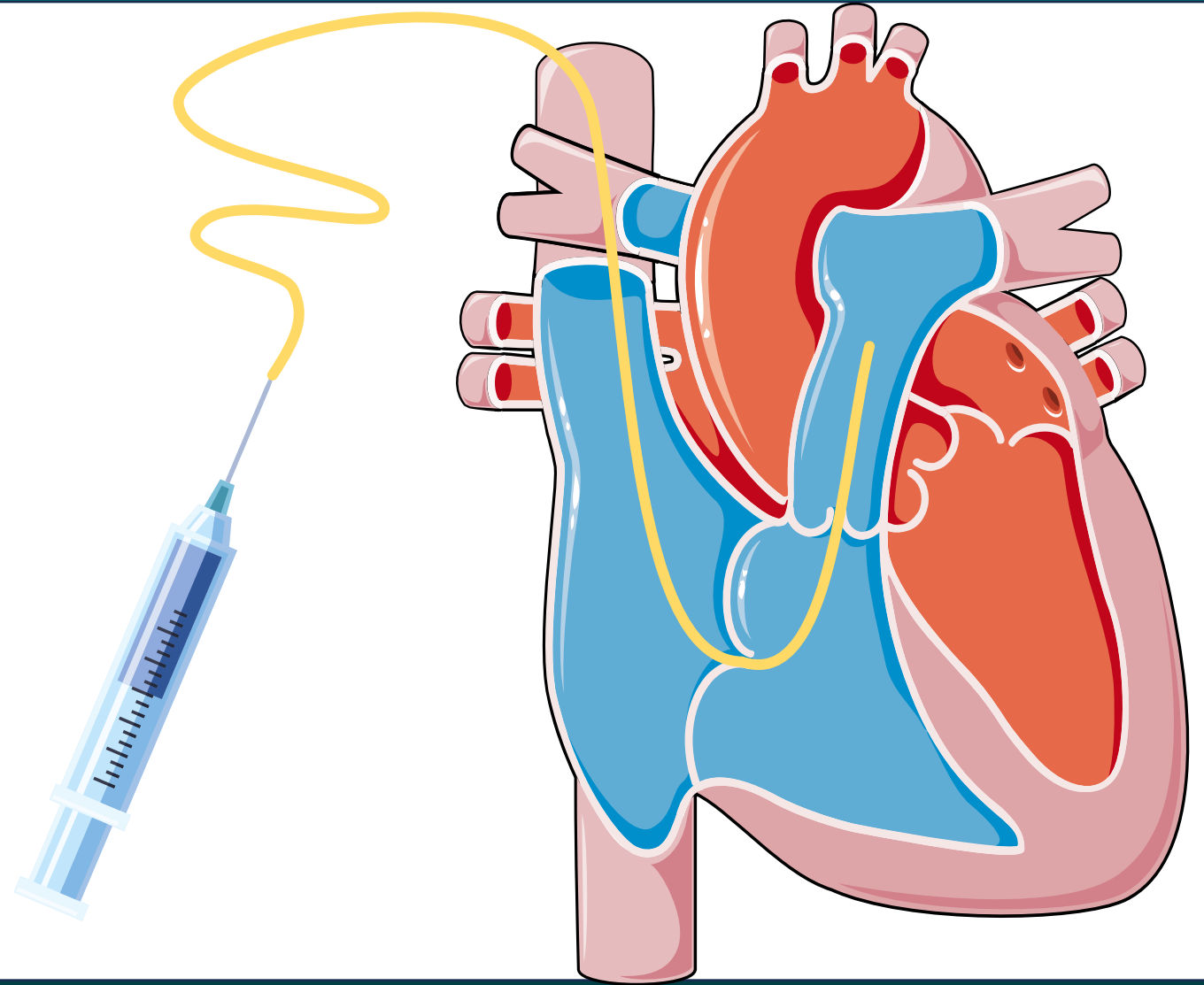


	Congenital Codes
Superior Vena Cava	75827
Inferior Vena Cava	75825
Second SVC imaging (after 75827)	93584
Azygos/hemiazygos venography	93585
Coronary sinus venogram	93586
Veno-venous collateral (at or <i>above</i> the heart)	93587
Veno-venous collateral venography below the heart	93588

Congenital Add-On Codes

93598:

Cardiac output measurement(s),
thermodilution or
other indicator
dilution method



Percutaneous Procedures

	Congenital Codes
Balloon Valvuloplasty; Aortic	92986
Balloon Valvuloplasty; Mitral valve	92987
Balloon Valvuloplasty; Pulmonary valve	92990
Pulmonary artery balloon angioplasty, single vessel	92997
each additional vessel	+92998
Pulmonary vein venoplasty (use for coronary sinus also)	37248
each additional vein	+37249

Question

True or False?

All procedure should be combined into 1 CPT code.

Question

False!

Things to Remember



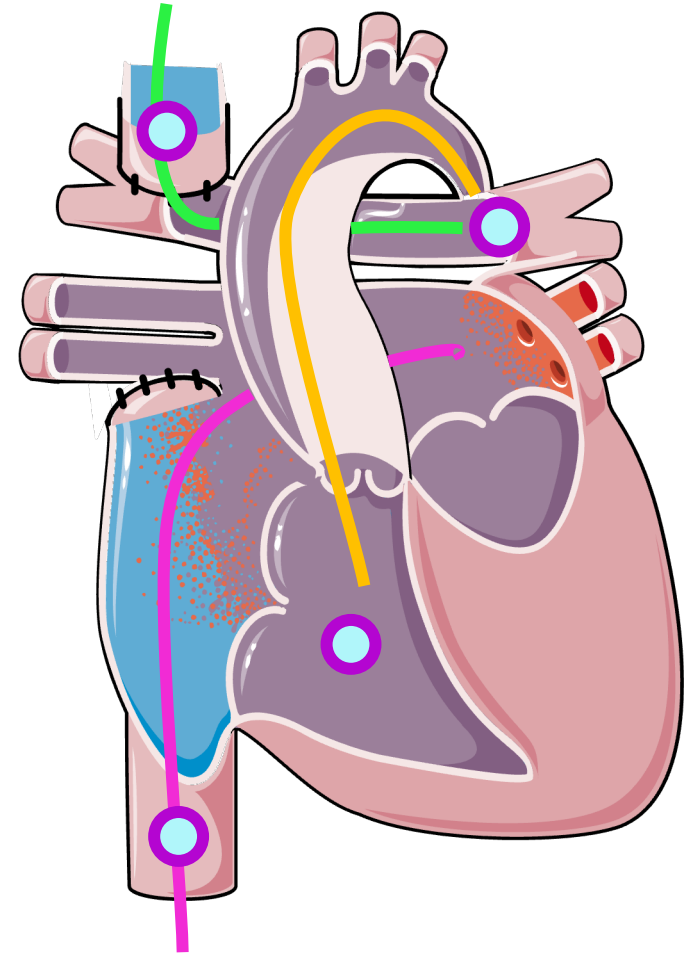
- 1) Is this a normal or abnormal connection?
- 2) Was the catheter placed in the right, left or both sides of heart?
- 3) What is the location of the angiograms?

Example

CLINICAL HISTORY: Patient is 5 months of age and is being followed for hypoplastic left heart disease.

PROCEDURE: A catheter was manipulated from the right femoral vein to IVC, right atrium, and to the left atrium. An additional catheter was manipulated from right internal jugular vein to SVC, right pulmonary artery and left pulmonary artery. A catheter was advanced from right femoral artery to descending aorta, ascending aorta, and systemic right ventricle.

Hemodynamic and oximetry data was obtained documented. Angiographies were obtained inside the SVC, systemic right ventricle, left pulmonary artery, and IVC, documenting good size pulmonary arteries with one venous collateral originating from innominate vein.



Example

What type of Connection?

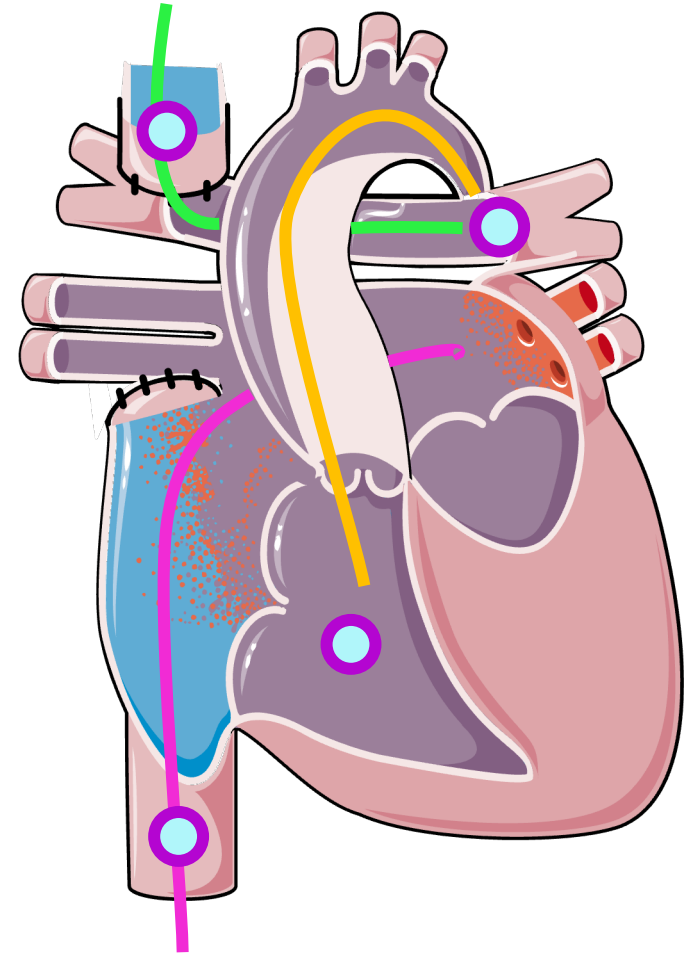
Abnormal

Right, Left or Both?

Right and Left

Angiograms?

L pulmonary, SVC, IVC, and Right Ventricle



Example

Abnormal Connection

93597: Right and Left Heart

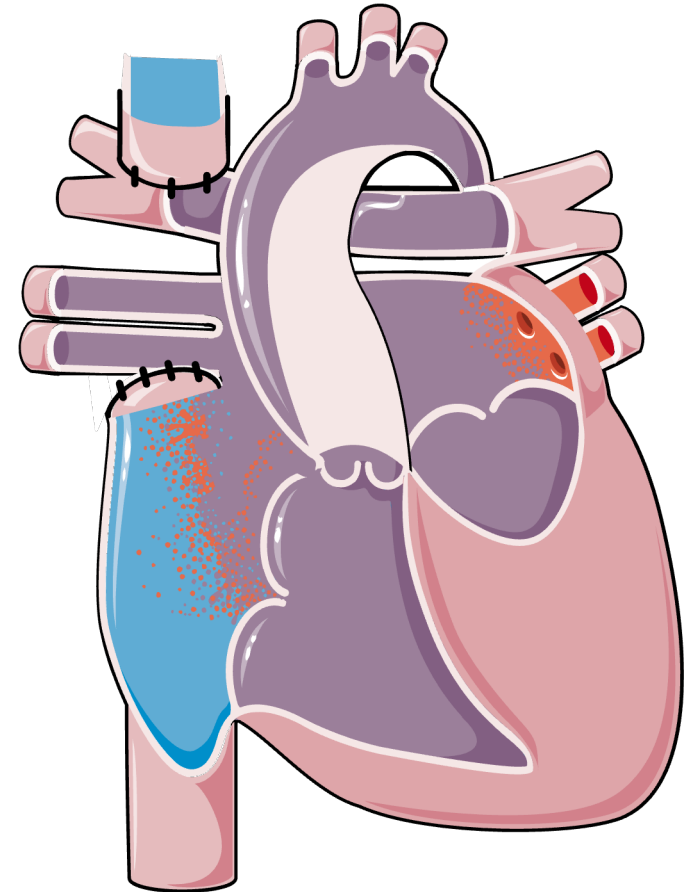
Angiograms:

93569: L pulmonary

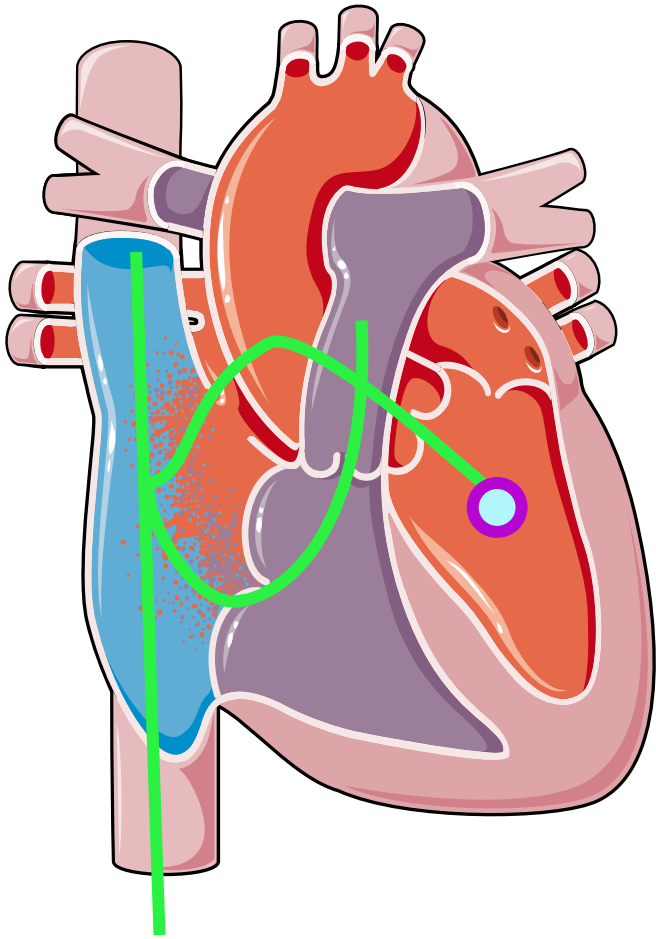
75827: SVC

75825: IVC

93566: Right Ventricle



Example: ASD



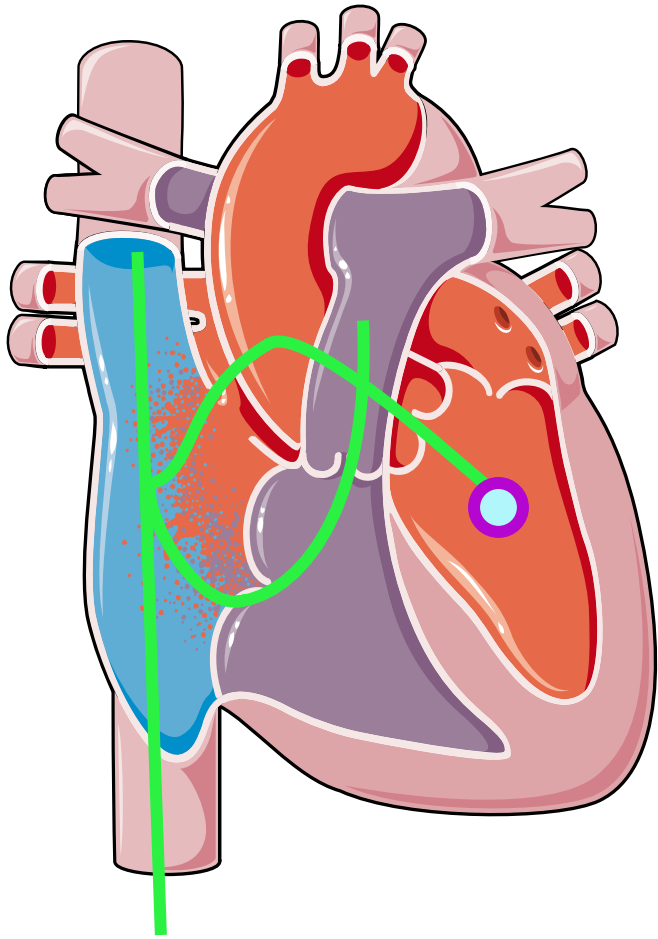
HISTORY: 46 yo patient diagnosed with secundum ASD on TEE, after c/o dyspnea, atypical chest discomfort and palpitation.

PROCEDURE: A wedge catheter was manipulated from the right femoral vein to IVC, right atrium and SVC, and subsequently from the right atrium to the right ventricle, distal left, and distal right pulmonary arteries. The catheter was pulled back to the right atrium and advanced across the ASD into left atrium and left ventricle. Hemodynamic and oximetry data were obtained. Angiographies were performed in left ventricle, coronaries.

CONCLUSIONS:

1. Known atrial septal defect. Qp: QS at atrial level of 2.5 to 1 at atrial level.

Example



What type of Connection?

Normal

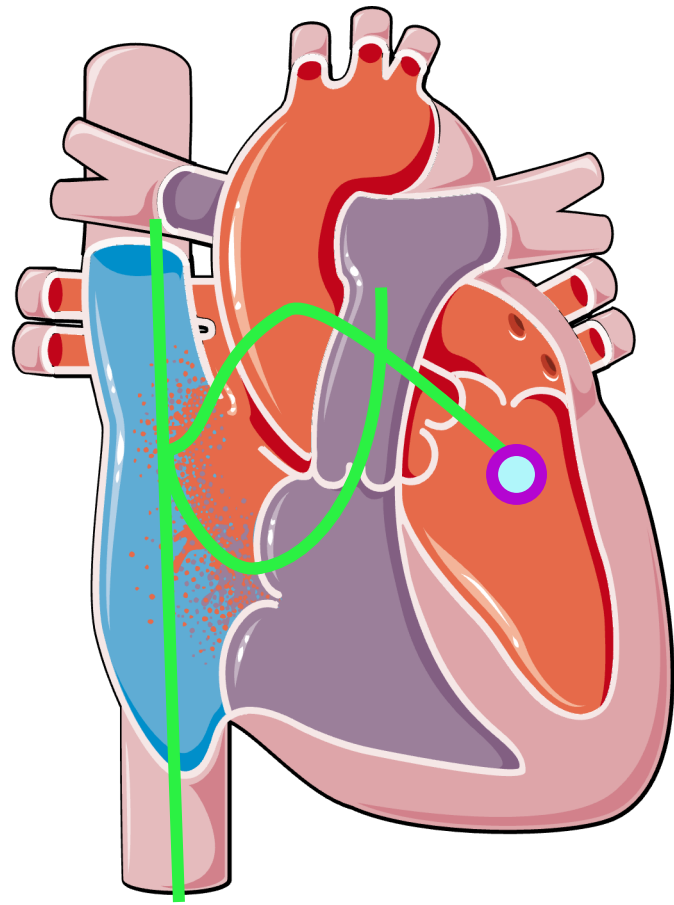
Right, Left or Both?

Right and Left

Angiograms?

Left Ventricle and Coronaries

Example



Normal Connection

93596: Right and Left Heart

Angiograms:

93565: Left Ventricle

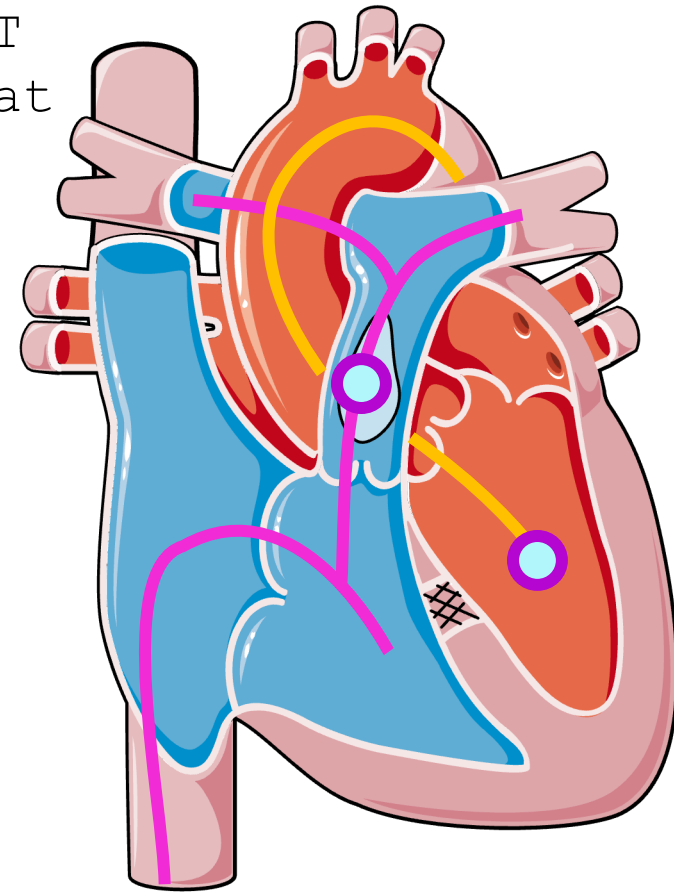
93563: Coronary

Example: Fallot Repaired

HISTORY: 82 yo patient with, h/o ToF s/p 1) Classic R-BT shunt at Johns Hopkins age 6 yo 2) TOF complete repair at age 30 yo at WCMC.

PROCEDURE: A wedge catheter was manipulated from the right femoral vein to IVC, right atrium and right SVC, and subsequently from the right atrium to right ventricle, main PA, left PA, and right PA. A Pigtail catheter was advanced from right femoral artery to descending aorta, ascending aorta and into the left ventricle.

Hemodynamic and oximetry data were obtained as listed below. Angiographies were performed in left ventricle, coronaries, and main pulmonary artery.



Example

What type of Connection?

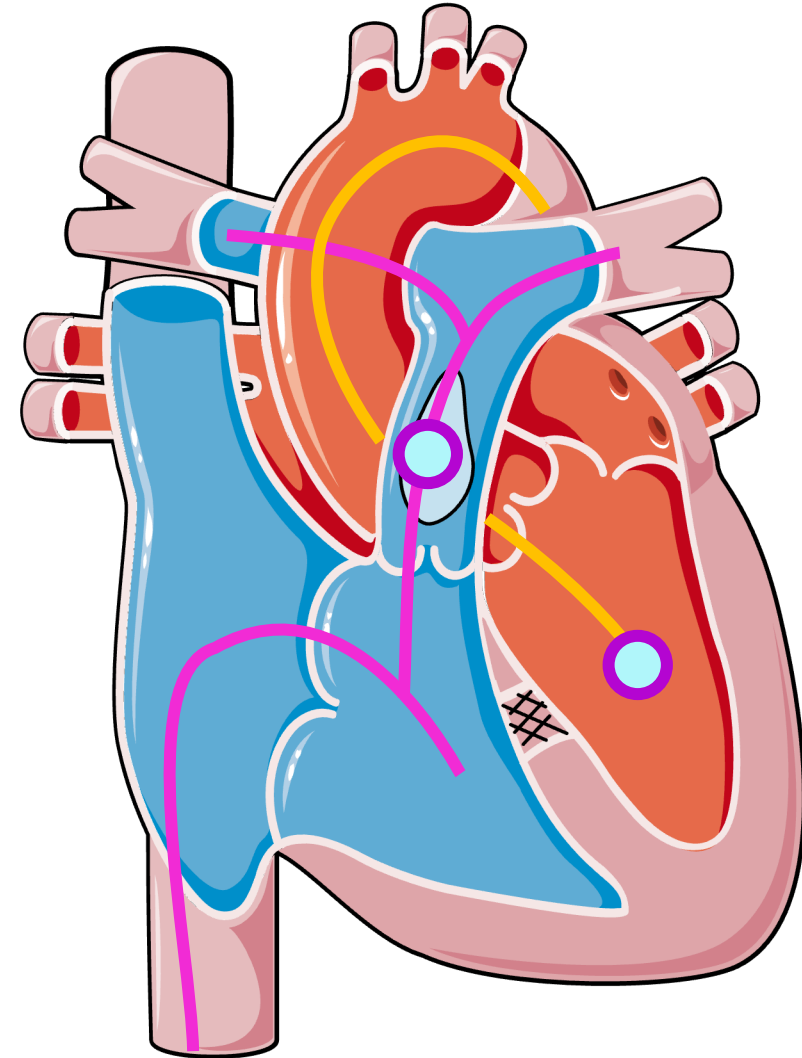
Normal

Right, Left or Both?

Right and Left

Angiograms?

Left ventricle, Coronaries, and
Main Pulmonary Artery



Example

Normal Connection

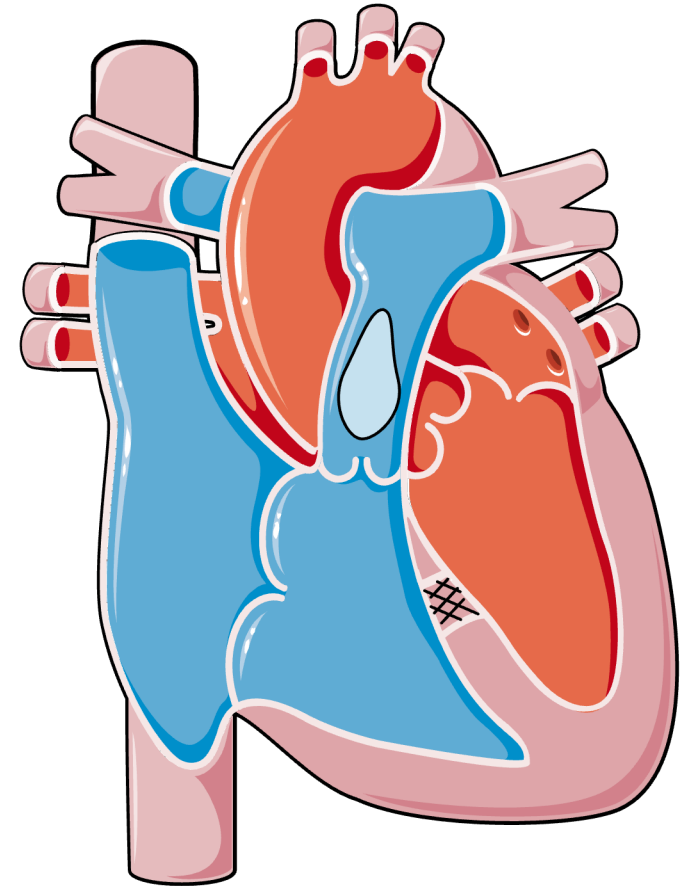
93596: Right and Left Heart

Angiograms:

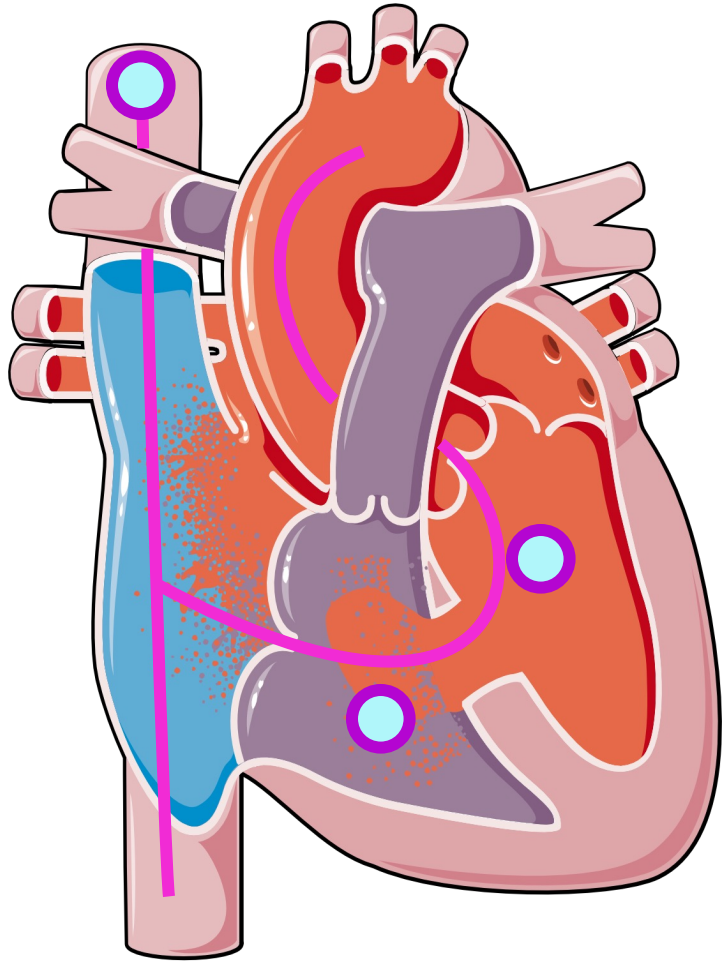
93565: Left Ventricle

93563: Coronary

93568: Non-Selective Pulmonary



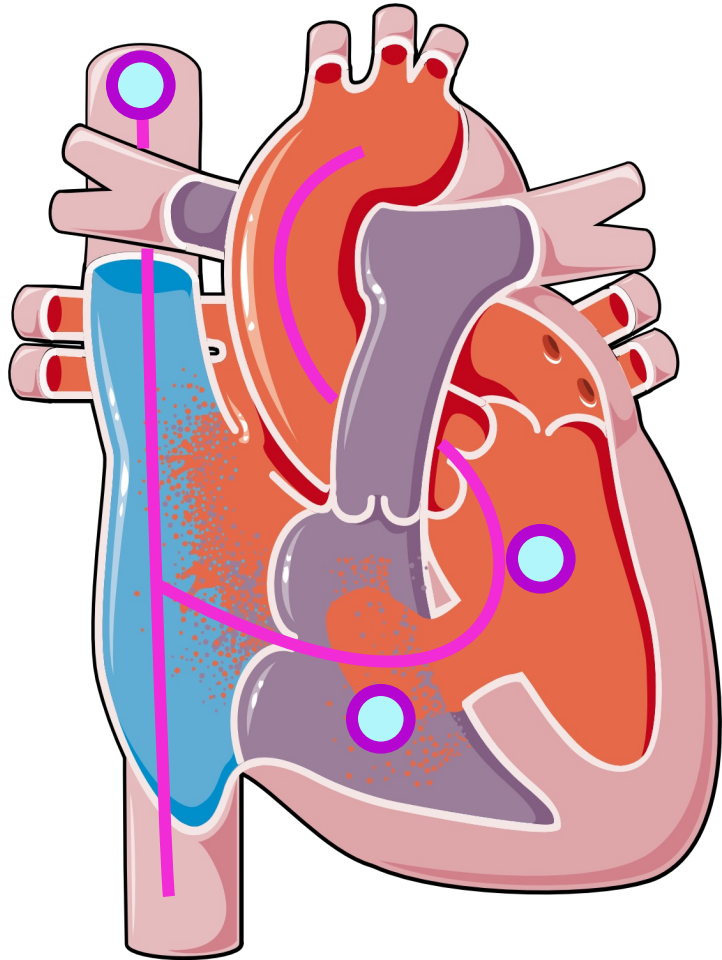
Example: ASD and VSD



History: Patient is a 3 yo diagnosed by echocardiography with a partial ventricular & atrial septal defect and an abnormal mitral valve.

PROCEDURE Using percutaneous technique, a 5 French sheath was placed in the left femoral vein and a 4 french sheath in the right femoral artery. Through the arterial and venous sheaths, a right and transseptal left heart catheterization was performed. A superior vena cava venogram was performed to demonstrate whether a left superior vena cava was present. A left ventriculogram was performed to demonstrate left ventricular function, size and the location and size of the ventricular septal defect. A right ventriculogram was performed to demonstrate the size of the right ventricle, patency of the tricuspid valve and the size of the pulmonary arteries. Hemodynamics were recorded both on room air and with 100% ambient oxygen.

Example



What type of Connection?

Normal

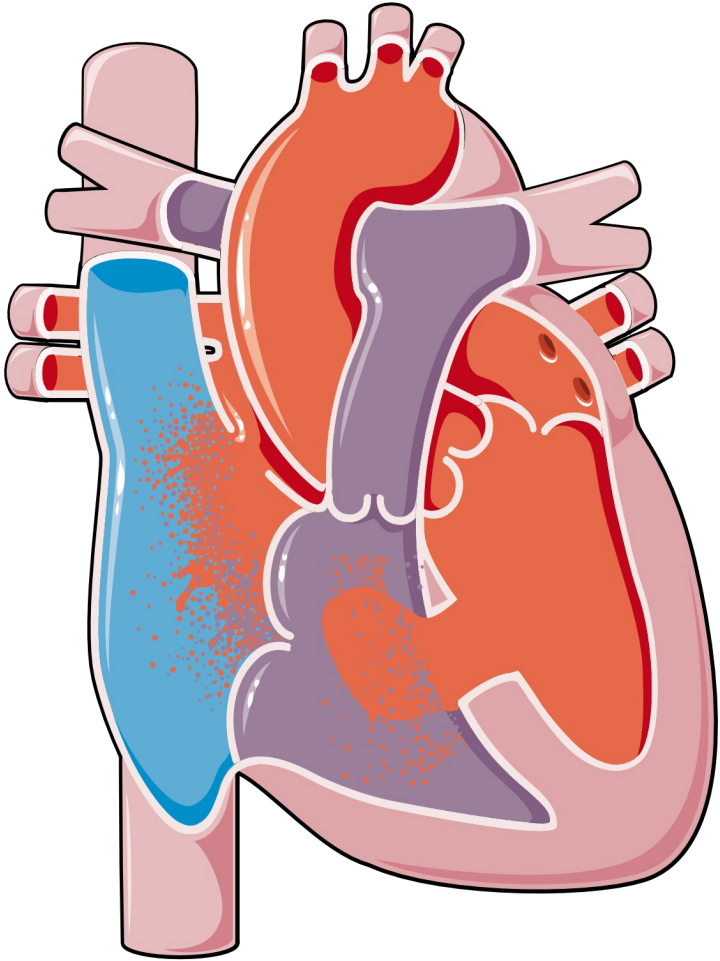
Right, Left or Both?

Right and Left

Angiograms?

SVC, Left Ventricle and Right Ventricle

Example



Normal Connection

93596: Right and Left Heart

Angiograms:

75827: SVC

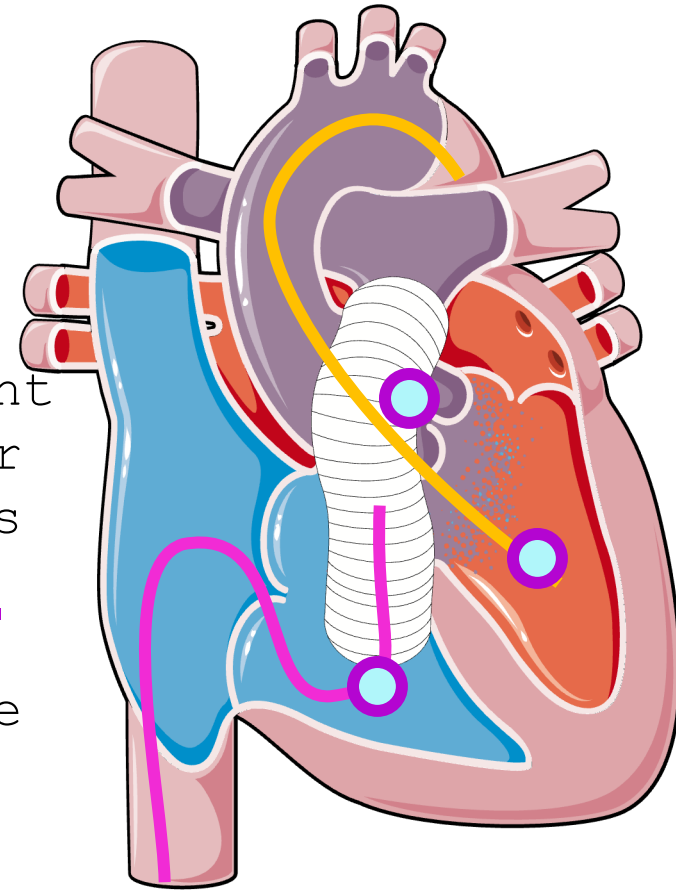
93565: Left Ventricle

93566: Right Ventricle

Example

History: Eight-year-old with a history of truncus arteriosus status post repair with closure of a VSD and placement of a pulmonary homograft.

Procedure: A right heart catheterization is performed with right ventricle angiography and non-selective pulmonary artery angiography, which reveals a significant gradient across the homograft valve. Retrograde catheter placement into left ventricle with hemodynamic pressures obtained. Left ventriculography is performed. An aortic root injection is then performed, revealing a severe dilation of the aortic root. A wire is placed across the homograft pulmonary valve followed by a 12 x 2 valvuloplasty balloon, which is inflated twice.



Example

What type of Connection?

Abnormal

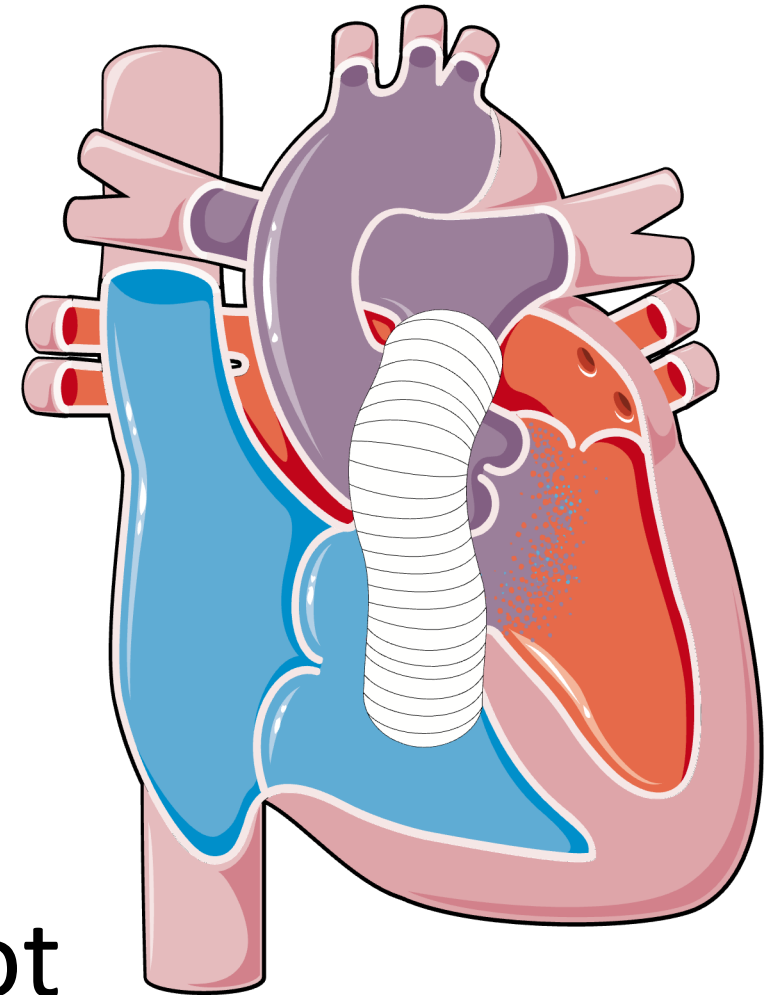
Right, Left or Both?

Right and Left

Angiograms?

Right ventricle, Main Pulmonary

Artery, Left ventricle & Aortic Root



Example

Procedure:

92990: Balloon Valvuloplasty; Pulm valve

Abnormal Connection

93597: Right and Left Heart

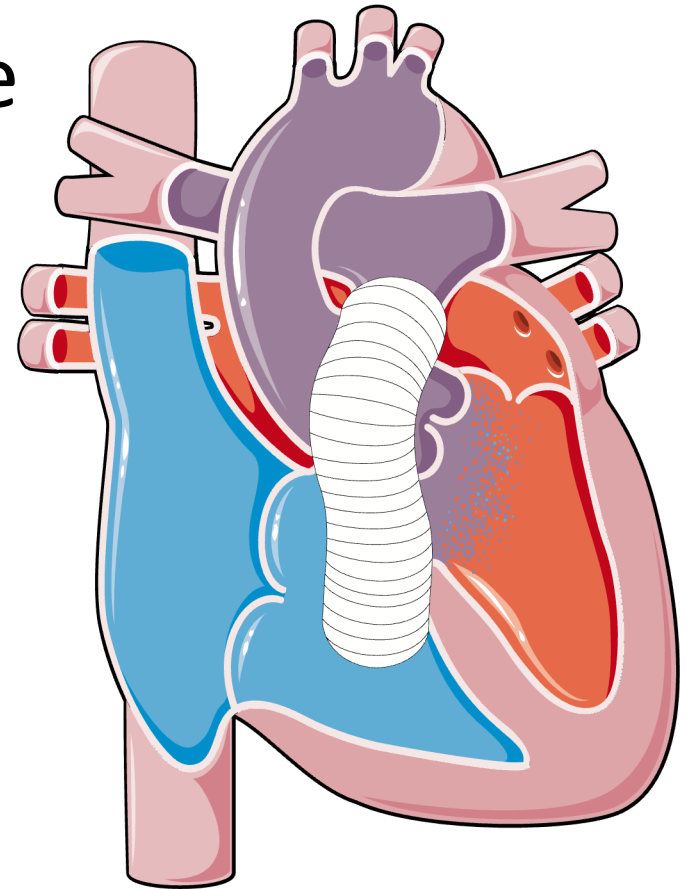
Angiograms:

93566: Right Ventricle

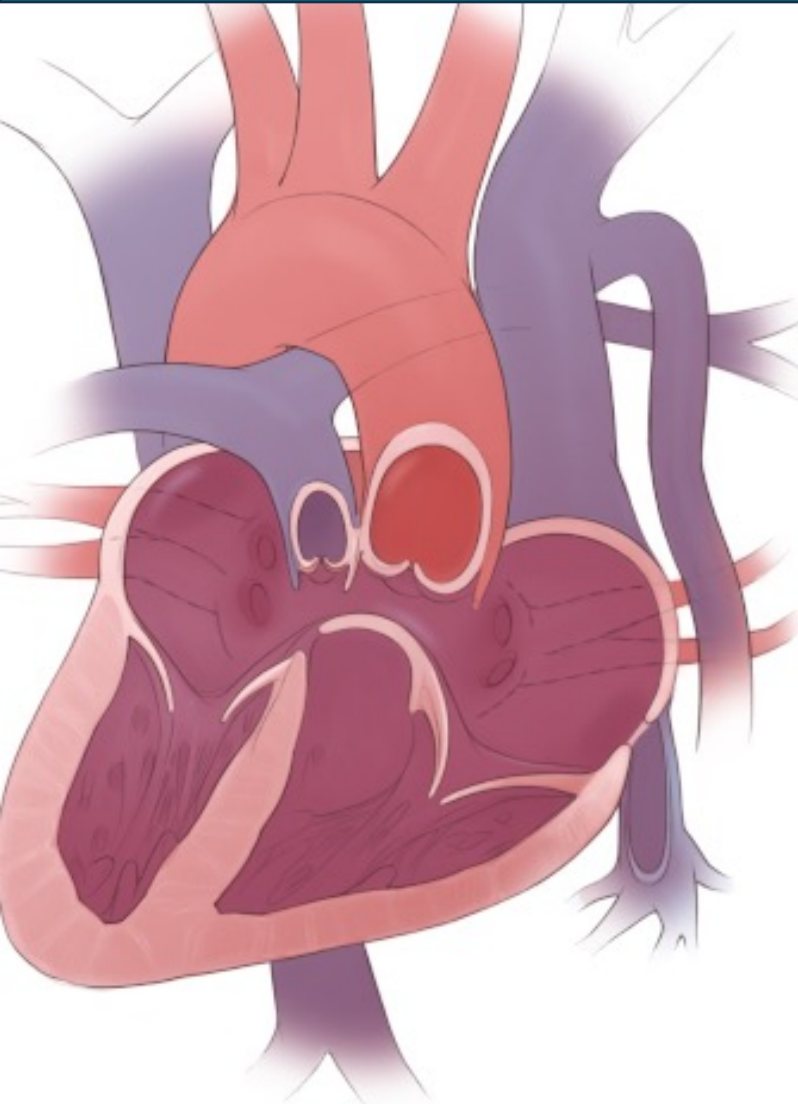93565: Left Ventricle

93568: Non-Selective Pulmonary

93567: Supravalvular aortography



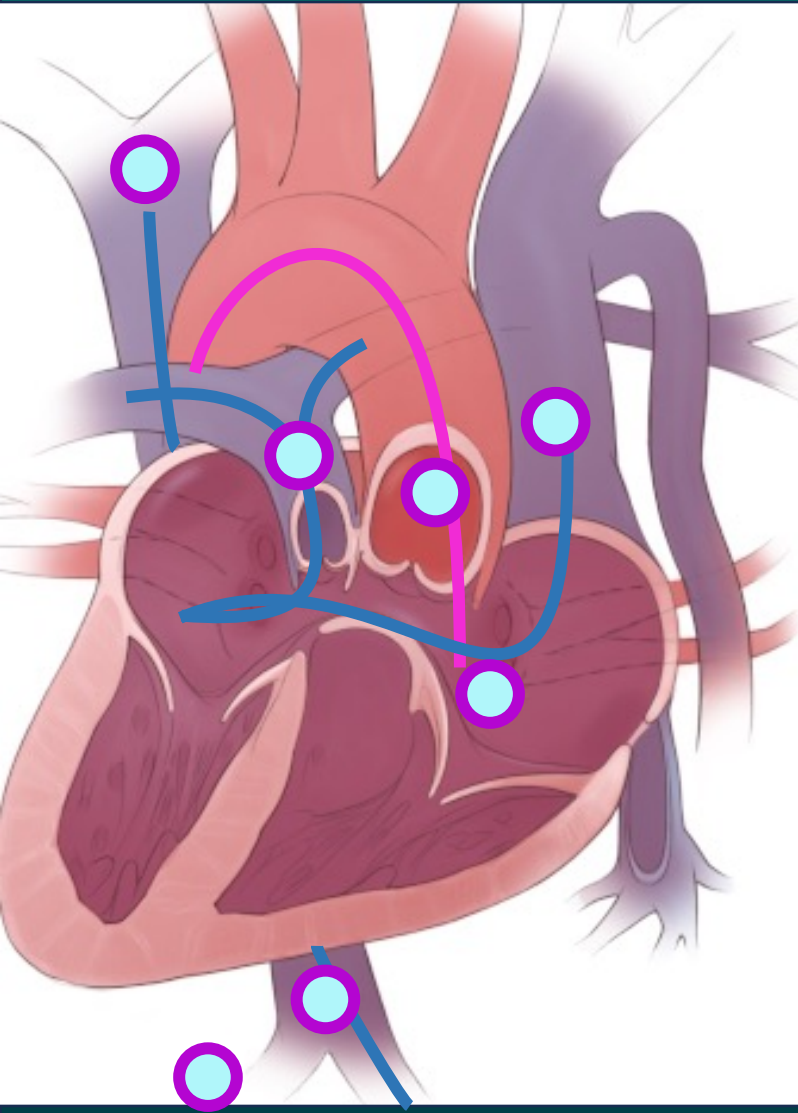
Example: Heterotaxy



History: Patient is 22 year old with a history of complex heart disease: **Heterotaxy, malposed greater arteries, bilateral SVC and pulmonary venous return to the ipsilateral side of the common atrium.** They underwent a bilateral **BiDirectional Glenn, MPA division** and intracardiac fenestrated **Fontan** (20mm conduit). They are being referred for a right and left heart.

PROCEDURE: After sterile draping, vascular access was obtained in the right femoral artery and right femoral vein.

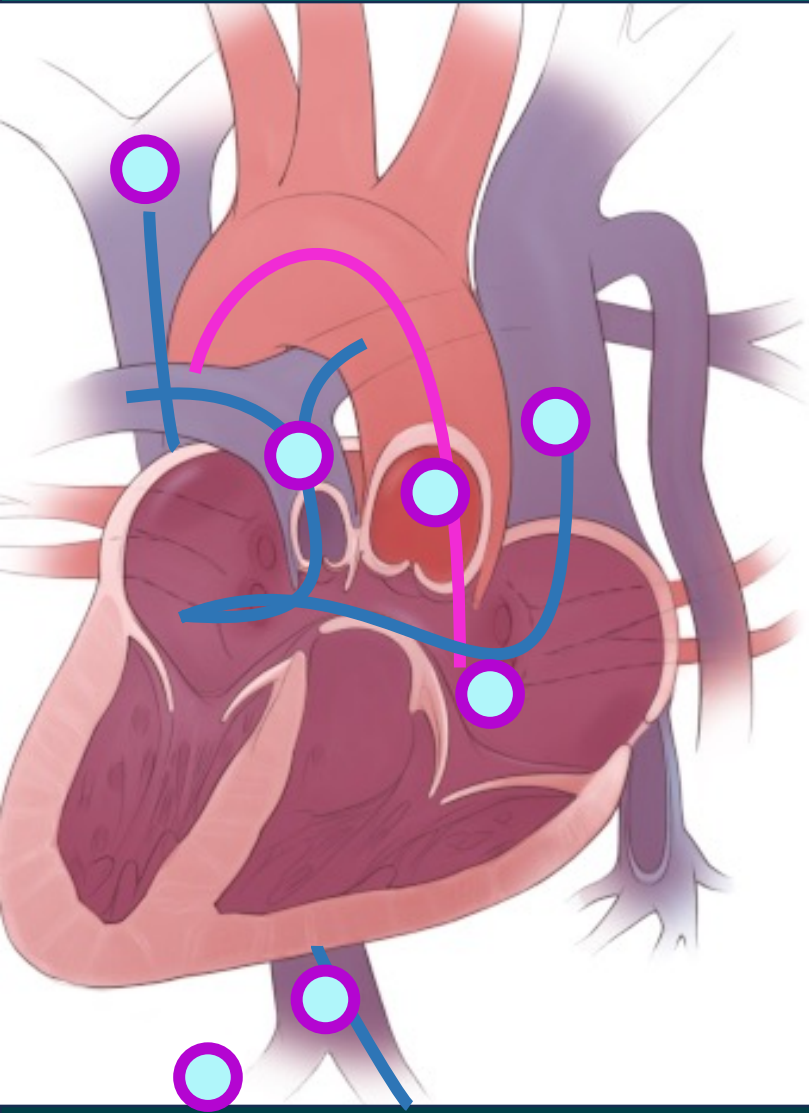
Example: Heterotaxy



PROCEDURE: A 6 French Pigtail catheter was advanced from right femoral artery to descending aorta, ascending aorta and into the left (common) ventricle. A 7-French wedge catheter was manipulated from the right femoral vein to the IVC, Fontan, right SVC, left & right PA and left SVC.

Hemodynamic and oximetry data were obtained as listed below. Angiographies were performed in R-SVC, lateral tunnel Fontan, main PA, L-SVC, IVC/hepatic vein, left (single) ventricle, and supravalvular aorta. At this point the hemostatic sheath were removed and manual pressure hemostasis obtained.

Example



What type of Connection?

Abnormal

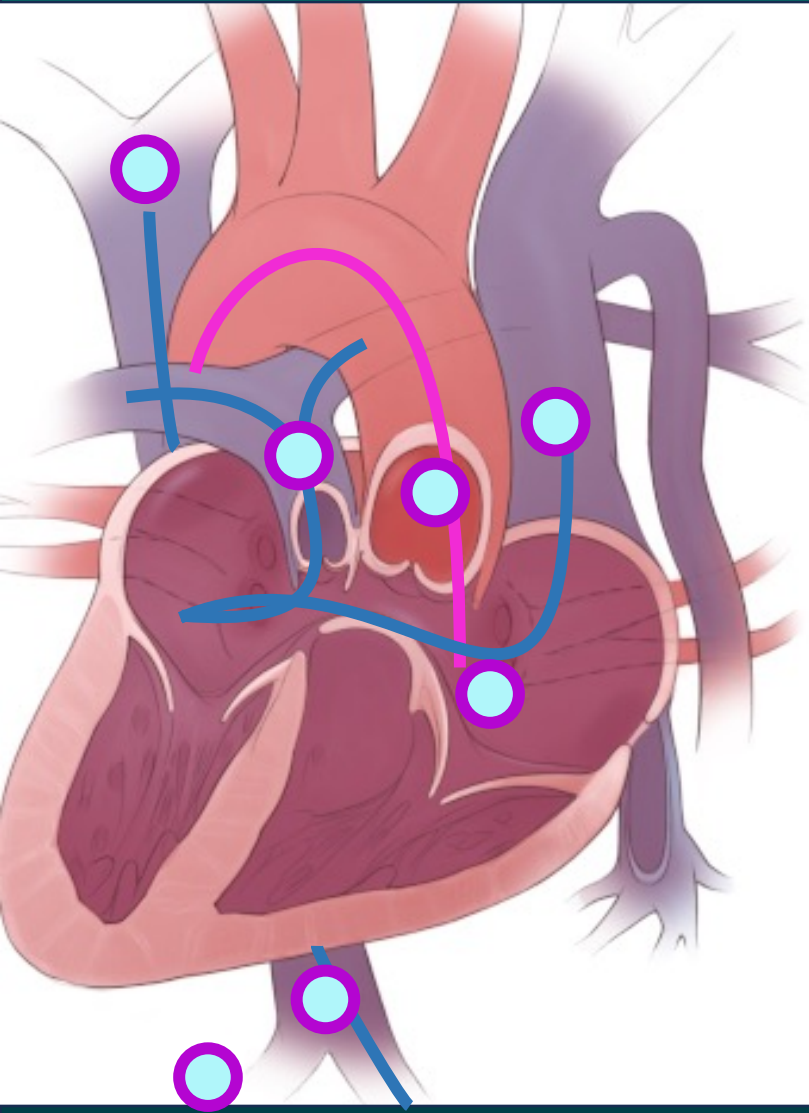
Right, Left or Both?

Right and Left

Angiograms?

R-SVC, Fontan (replaces RV), main PA, L-SVC, IVC/hepatic vein, left (single) ventricle, and supra-valvular aorta

Example



Abnormal Connection

93597: Right and Left Heart

Angiograms:

75827: SVC

75825: IVC

93584: Persistent SVC

93565: Left Ventricle

93566: Fontan (Right Ventricle)

93568: Non-Selective Pulmonary

93567: Supravalvular aortography

75889: Hepatic Venogram

36011: 1st order catheterization

Adults with Heart Defects

Once a patient is diagnosed with a congenital heart defect (CHD), he/she should always be coded as such.

Exceptions:

- Patient has a heart transplant
- Patient presents for acute MI

Non-Congenital Heart Disease

Isolated Patent Foramen Ovale

bicuspid aortic valve

mitral valve prolapse

anomalous coronary arteries arising off the aorta or other coronary arteries

Cardiomyopathy

Kawasaki's disease

Pericarditis

myocarditis (e.g., COVID-19)

primary pulmonary hypertension

valvular disease resulting from rheumatic fever

Normal Connections

Atrial Septal Defect

Ventral Septal Defect

Patent Ductus Arteriosus

Tetralogy of Fallot repaired (where pulmonary valve stenosis, VSD, and overriding aorta are repaired)

Abnormal Connections

truncus arteriosus

hypoplastic right or left heart

double outlet right ventricle

tetralogy of Fallot

Total Anomalous Pulmonary
Venous Return

Partial Anomalous Pulmonary
Venous Return

transposition of the great arteries

Scimitar syndrome

valve atresia

Dextrocardia

Heterotaxia

endocardial cushion defect

**Thank you for
attending today!**

Do you have any questions?

CPT Assistants:

- Ballooning of a right ventricular outflow tract conduit when a stent is not placed, correction; CPT Assistant, August 2024, Page: 1
- Venography for congenital heart defects; CPT Assistant, April 2024 Page: 1
- Pulmonary angiography reporting; CPT Assistant, May 2023 Page: 1
- Cardiac Catheterization For Congenital Heart Defects; CPT Assistant, April 2022 Page: 12

- Images:
 - Congenital heart <https://smart.servier.com/>
 - Tetralogy of Fallot: <https://step1.medbullets.com/cardiovascular/108029/tetralogy-of-fallot>
- Coding
 - zHealth Cardiology: <https://www.zhealthpublishing.com/coding-products/>
- ncbi.nlm.nih.gov
- sciencedirect.com/science/article/pii/S187521361930138X
- AMAs Editorial Panel (2027 changes):
 - <https://www.ama-assn.org/about/cpt-editorial-panel/summary-panel-actions>

Feedback



CodingConduit.com

AmyClay@CodingConduit.com

[LinkedIn: Amy Clay, CCS, CIRCC](#)

More exciting things to come!